

The role of echocardiography in the embolic stroke of undetermined source

Alessandra Danese^a, Giacomo Mugnai^b, Francesca Prevedello^b, Michele Morra^a and Claudio Bilato^b

Echocardiography plays an important role both in the diagnosis and the treatment/prevention of embolic stroke of undetermined source and should be performed as soon as possible for preventing ischemic stroke recurrences, which occur more frequently during the first week after the first ischemic event. Early identification of the cause of a transient ischemic attack or stroke is indeed a primary goal for the neurologist in the Stroke Unit and requires specific diagnostic strategies. Echocardiography, together with other diagnostic tools such as carotid and transcranial ultrasounds, provides this information promptly. In particular, echocardiography might be able to detect the main sources of the embolic stroke, such as atrial fibrillation, ventricular akinesia, aortic atheroma plaques and/or cardiac shunts. The present review discusses the

importance and the practical role of echocardiography as a crucial diagnostic tool for detecting the main source of emboli in the setting of the acute stroke.

J Cardiovasc Med 2020, 21:547–555

Keywords: atrial fibrillation, echocardiography, embolic stroke

^aDivision of Neurology and ^bDivision of Cardiology, West Vicenza General Hospitals, Vicenza, Italy

Correspondence to Giacomo Mugnai, MD, PhD, Division of Cardiology, West Vicenza General Hospitals, Via del Parco, 1, Arzignano, 36071 Vicenza, Italy
Tel: +39 0444479106; fax: +39 0444479359;
e-mail: mugnai.giacomo@gmail.com

Received 20 December 2019 Revised 5 April 2020
Accepted 11 April 2020

Introduction

Stroke is the third cause of death in the industrialized countries and is responsible for significant morbidity and mortality.¹ Twenty to thirty per cent of ischemic strokes are embolic²; echocardiography has a major role to identify the sources of the emboli and is highly recommended in most of the clinical guidelines on stroke^{3,4} (Fig. 1).

Echocardiography plays an important role both in the diagnosis and the treatment/prevention of the cardiac source of embolism. It should be performed as soon as possible for preventing recurrences, which occur more frequently during the first week after the first stroke or transient ischemic attack (TIA).⁵

On the contrary, in daily clinical practice transthoracic echocardiography (TTE) is not routinely performed early after the hospital admission, mostly because of organizational problems. This delay leads to longer in-hospital stay and increases the costs for the Healthcare Systems.⁶

By contrast, a simplified TTE approach performed in the early days following the acute cerebrovascular event and focused on the detection of the main embolic sources may reduce the in-hospital stay by providing reliable diagnoses of the embolic stroke cause.^{7,8}

The importance and the practical role of echocardiography in identifying the main sources of emboli in acute stroke will be discussed herein.

The embolic stroke

Clinical characteristics

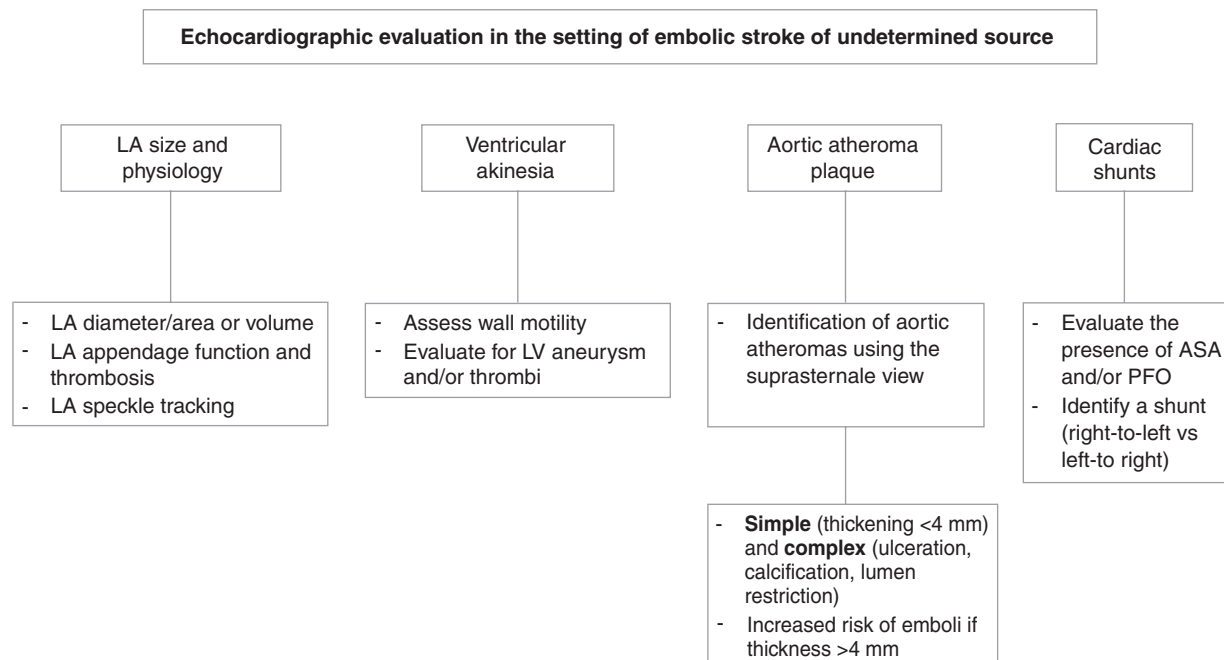
Several peculiar clinical and imaging features allow the embolic stroke to be differentiated from other stroke subtypes.

Sudden onset of symptoms is more frequent in embolic stroke compared with other strokes and occurs in 25–82% of cases. By contrast, history of previous TIAs is unusual in embolic stroke and is more common in large vessel atherosclerotic disease.⁹ Embolic cause is frequently associated with fluctuations of symptoms and transient clinical improvement before the occurrence of irreversible brain damage may occur. This phenomenon is due to the fragmentation of the emboli with reperfusion and recanalization of the ischemic brain tissue, and/or recruitment of collateral sources of blood flow.^{10,11}

The vessel most commonly involved is the middle cerebral artery or its branches, followed by basilar and anterior cerebral arteries.¹²

In terms of territorial distribution, the infarct affects a large portion of the cortex with a typical V-shape or the subcortical lenticulostriate region. In particular, a pattern of multiple infarctions involving multiple cerebral areas is suggestive for brain embolism. Sometimes, acute emboli are visualized as hyperdense arteries at the noncontrast cranial tomography, in absence of significant carotid plaques.^{13–15} Finally, embolic stroke shows more hemorrhagic evolution (about 20% of all embolic stroke), due

Fig. 1



Flowchart of the main diagnostic targets during transthoracic echocardiography in the setting of an embolic stroke of undetermined source. ASA, atrial septal aneurysm; LA, left atrial; LV, left ventricular; PFO, patent foramen ovale.

to the spontaneous lysis of the thrombus into the infarcted tissue once the reperfusion resumes.¹⁶

In the presence of suspected clinical and radiological findings of embolic stroke, echocardiography evaluation is very precious and valuable for the prompt characterization of the embolic source.

Possible sources of embolic stroke

Many conditions may lead to cerebral embolism, making embolic stroke a heterogeneous entity. The heart is the major source of emboli, as blood clots, tumor fragments, infected and bland (non infected) vegetations, calcified particles and atherosclerotic debris.⁴ The conditions predisposing to cerebral embolism can be classified as 'high-risk' and 'low-risk' and are shown in Table 1.

Atrial fibrillation (AFib) is a common arrhythmia with increasing prevalence with age (from 0.4 to 1% in general population to 9% in people age 80 or older). The risk of stroke or embolism in AFib patients ranges from 1% (low-risk) to 15% (high-risk) per year¹⁷ and is related to the loss of organized electrical/mechanical activity, which causes stasis of blood inside the atria, especially in the left atrial appendage,¹⁸ and ultimately thrombus formation.

Myocardial infarction (MI) is another important predisposing condition for cerebral embolism. The incidence of left ventricular (LV) thrombus in acute coronary syndrome

ranges between 5 and 15%, despite optimal medical therapy.^{19,20} Notwithstanding the high incidence of thrombus formation, the incidence of embolic stroke is relatively low²¹ and commonly occurs 14 days after the MI.²² More frequently, thrombi in the LV developed in large infarcts, anterior MIs, severe apical wall motion abnormalities and in the presence of LV aneurysm.²³ Thrombus formation during MI is related to subendocardial injury, which results in blood stasis; in addition, a hypercoagulable state with activated procoagulant factors and decreased physiologic anticoagulant activity may contribute to the thrombus formation. The incidence of embolization is higher for mobile thrombi and lower for mural ones.^{24,25} In patients with previous MI and severely impaired LV function the

Table 1 Cardioembolic sources

Major risk sources
Atrial fibrillation
Recent or previous myocardial infarction
Cardiomyopathies
Intracardiac tumor (myxoma, papillary fibroelastoma)
Rheumatic valve disease (mitral stenosis) and mechanical valve prosthesis
Aortic arch atheromatous plaques
Endocarditis
Minor or unclear risk sources
Mitral valve prolapse
Mitral annulus calcification
Calcified aortic stenosis
Atrial septal aneurysm
Patent foramen ovale
Giant Lambli's excrescences

risk of stroke is noticeable, especially when the LV ejection fraction is 28% or less.²⁶

Even a modest reduction in the LV ejection fraction might represent the 'nidus' for thrombus formation with an increased risk of embolic stroke.^{27,28} A recent retrospective, cross-sectional study on patients with acute ischemic stroke enrolled in the CAESAR (Cornell Acute Stroke Academy Registry) showed that a lower LV ejection fraction was associated with embolic stroke of undetermined source after excluding the individuals with ipsilateral carotid atherosclerosis.²⁷ A previous Korean study also found that an LV wall motion abnormality was independently associated with an elevated risk of recurrent stroke.²⁸

In patients with LV dilatation due to ischemic or non-ischemic diseases, the risk of embolic stroke is not neglectable. Compared with restrictive and hypertrophic cardiomyopathies, mural thrombus formation is more common in dilated cardiomyopathy with a ranging incidence between 1.7 and 18%.²⁹ The main reasons for thrombus formation are the blood stasis and the loss of normal subendocardial trabeculation, which has the function 'to squeeze' the blood away from the endocardial surface. Moreover, AFib is associated with several cardiomyopathies and further increases the risk of embolism in these patients.³⁰

Cardiac masses such as intracardiac tumors are rare but important causes of cerebral embolism. Myxomas account for about 30–50% of all primary cardiac tumors; they are more frequent in women and usually localized in the left atrium (LA) attached to the fossa ovalis (90%). Embolism occurs in 30–50% of patients with cardiac myxomas.^{31,32}

Rheumatic valve disease still remains an important cause of brain embolism, although the incidence of rheumatic fever has dramatically declined in Western countries. Progressive mitral valve stenosis leads to increased intra-atrial pressure and progressive dilatation of LA; the final result is blood stasis and higher risk of thrombus formation, although the incidence of thromboembolism does not correlate with the degree of LA enlargement and the severity of mitral stenosis in sinus rhythm.^{33,34} The presence of AFib, however, considerably increases the risk of embolism.^{35,36}

Mechanical valve prostheses represent an important risk factor for cerebral embolism secondary both to infection and endocarditis and to prosthetic valve thrombosis. Prosthetic valve thrombosis affects mostly tricuspid and mitral valves. The estimated annual risk is 1–2%, regardless of anticoagulation, whereas results are 0.5–1% for bioprosthetic valves.⁴ Early postoperative period, pregnancy and interruption of the anticoagulant therapy increase the risk of prosthetic valve thrombosis.³⁷ Thrombus formation is related not only to the intrinsic

thrombogenicity of the prosthetic material but also to the alteration of the blood flow.

Aortic atherosclerosis is a risk factor for stroke, regardless of other factors including AFib and carotid artery disease.^{38–40} The prospective French Study of Aortic Plaques in Stroke demonstrated that aortic wall thickness at least 4 mm identified on transesophageal echocardiogram (TEE) strongly predicted ischemic stroke.⁴¹ Ulcerated and soft plaques without calcifications are also related to higher risk.⁴² Aortic arch atherosclerosis is reported in 60% of individuals aged 60 or older with cerebral infarction.⁴³ Complex aortic plaques (thickness ≥ 4 mm, ulceration or mobile components) are visualized in 21–27% of patients with ischemic cerebrovascular disease.⁴⁴ Moreover, a recent meta-analysis showed that aortic atheromas increased the risk of stroke by about four times.⁴⁵

The risk of embolism in endocarditis is 10–50% but the real incidence is unknown because several embolic events are clinically silent.⁴⁶ The risk of embolization becomes higher if the size of vegetation is more than 10 mm and it is mobile.⁴⁷

Minor or unclear causes of embolism included patent foramen ovale (PFO) and atrial septal aneurysm (ASA), mitral valve prolapse, mitral annulus calcification, calcified aortic stenosis and giant Lambli's excrescences. The most relevant feature, which may have a significant correlation with the embolic stroke, is the PFO, a remnant of the fetal circulation that remains patent in about 20–25% of the adult population.⁴⁸ By facilitating the right-to-left shunt, some PFO anatomical characteristics provide additional risk of TIA or stroke in young people: the presence of ASA (≥ 10 -mm septal excursion during cardiac cycle),^{49,50} a PFO diameter at least 4 mm,⁵¹ the presence of Eustachian Valve or Chiari's network. Paradoxical embolism can be promoted by inherited or acquired thrombophilia, conditions predisposing thrombosis in the pelvic and lower extremity veins such as cancer, recent surgery, pregnancy and all the situations entailing the Valsalva maneuver.

In all the other minor causes (Table 1) the relationship with embolic stroke remains controversial.

Embolic stroke of undetermined source: a new concept

About 25% of the ischemic strokes are defined as cryptogenic because a clear cause cannot be identified. According to the TOAST classification,⁵² a cryptogenic stroke can result from: an incomplete negative investigation, more than one possible cause, or the absence of a defined cause after extensive investigation. Assuming that the majority of cryptogenic strokes are embolic, the new term ESUS (Embolic Stroke of Undetermined Source)⁵³ has been coined.

The diagnosis of ESUS is based on the following criteria: first, not lacunar stroke detected by computed

tomography (CT) or MRI (≤ 1.5 – 2.0 cm on MRI images in largest dimension, including on MRI diffusion-weighted images, and in the distribution of the small, penetrating cerebral arteries); second, absence of extracranial or intracranial atherosclerosis determining at least 50% luminal stenosis in arteries supplying the area of ischemia; third, no major-risk cardioembolic source of embolism, such as permanent or paroxysmal AFib, sustained atrial flutter, intracardiac thrombus, prosthetic cardiac valve, atrial myxoma or other cardiac tumors, mitral stenosis, recent (< 4 weeks) MI, LV ejection fraction of 30% or less, valvular vegetations or infective endocarditis; fourth, no other identified cause of stroke (e.g. arteritis, dissection, migraine/vasospasm and drug abuse).

The standard diagnostic examinations to define ESUS are brain CT or MRI, 12-lead ECG, TTE, ECG monitoring for at least 24 h with automated rhythm detection and imaging of the both extracranial and intracranial vessels supplying the area of brain ischemia (arteriography, MRI, CT, cervical and transcranial Doppler ultrasonography).

Several medical conditions such as nonstenotic plaques of cerebral arteries and other cardioembolic sources (e.g. aortic valve stenosis, mitral annular calcification, moderate systolic or diastolic dysfunction) with a lower arterioembolic risk and uncertain association with stroke can still be considered causes of ESUS (Table 2).

The new concept of ESUS is based on the assumption that most cryptogenic strokes are embolic. A substudy of Warfarin-Aspirin Recurrent Stroke Study (WARSS)⁵⁴ has shown the superiority of warfarin compared with aspirin in patients with cryptogenic stroke with an embolic topography at CT. Similarly, the ESPRIT trial⁵⁵ reported that warfarin was superior to aspirin in patients with a supposed arteriogenic ischemic stroke (i.e. not specifically restricted to cryptogenic strokes). By contrast, a recent large randomized prospective trial (NAVIGATE ESUS⁵⁶) showed that rivaroxaban was not superior to aspirin in preventing stroke recurrences after an initial ESUS but was associated with a higher bleeding risk.

Two other similar trials are ongoing: the RE-SPECT ESUS,⁵⁷ comparing dabigatran 110 or 150 mg twice daily with aspirin in approximately 6000 patients and 550

centers, and the ATTICUS,⁵⁸ comparing apixaban 5 mg twice daily with aspirin in approximately 500 patients.

Echocardiography plays an important role in ESUS, both to rule out patients with major risk of cardioembolic source and to characterize individuals with potential minor risk cardioembolic sources, allowing the most appropriate clinical management of a cerebrovascular event of undetermined source.

Echocardiography in the acute setting of embolic stroke

The main goal of TTE is the detection of the cause of embolic stroke. The examination should be performed with a conventional 2-dimensional second harmonic-enhanced echocardiogram through different thoracic views: parasternal (left parasternal long axis and short axis view), apical (four, five and three chambers view), subcostal and suprasternal sections.

The TTE should be preferentially performed within the first 2 days since admission in the Stroke Unit but can be also done in the Emergency Department, in case of strong suspicion of embolic stroke when the risk of recurrence is high.⁵⁹

Early identification of the cause is indeed a primary aim for the neurologist in the Stroke Unit, allowing more specific diagnostic strategies and the most appropriate therapeutical management. In this regard, echocardiography (and other diagnostic tools such as carotid and transcranial ultrasounds) can achieve a lot of information in a simple and prompt way and may detect the embolic source, as described below.

The left atrial size and physiology

LA evaluation by echocardiography is important not only for detecting the presence of thrombus, but also for analyzing the anatomical characteristics favoring AFib, to identify the patients who require strict monitoring for AFib and appropriate therapeutical management.

LA enlargement is associated with higher thromboembolic risk, poor maintenance of the sinus rhythm and worse prognosis.⁶⁰ A clear relationship exists between dilated LA and incidence of AFib and stroke.^{61–64} Although the left atrial size can be expressed by the anterior-posterior diameter or by the left atrial area,⁶⁵ the most accurate measuring method according to the guidelines is the left atrial volume, preferentially indexed to the body size.⁶⁵

The left atrial appendage (LAA) is the major source of thromboembolism in stroke patients with AFib.^{66–68} Although transoesophageal echocardiography (TEE) is the gold standard technique to detect LAA thrombi, recent studies demonstrated that TTE can be also

Table 2 Medical conditions with a potentially lower arterio-embolic risk

Covert paroxysmal atrial fibrillation
Aortic arch atherosclerosis plaques
Cerebral artery plaques with ulceration $\leq 50\%$
Patent foramen ovale/atrial septal defect/atrial septal aneurysm/Chiari network
Mitral/aortic valve calcification
Aortic valve stenosis
Mitral valve prolapse
Dysrhythmias (e.g. atrial high-rate episodes, atrial asystole and sick-sinus syndrome)
Moderate systolic or diastolic dysfunction of the left ventricle

effective to study LAA function in a large number of patients.^{69,70}

Left atrial mechanical remodeling is associated with left atrial wall deformation (the strain of the LA), and with thrombus formation in LAA.^{71–73} The measurement of the left atrial strain (by speckle tracking) is a novel technique which using standard B-mode images evaluates the longitudinal shortening and lengthening of different left atrial segments throughout the cardiac cycle by means of acoustic backscatter generated by the ultrasound beam. The changes between speckles are assumed to represent the strain.⁷⁴ A decreased left atrial strain suggests a worse mechanical function of the LA and is associated with the development of AFib. A reduction in left atrial strain has been reported in patients with paroxysmal AFib, stroke or TIA, and low-risk CHADS₂ score⁷⁵; a pilot study also reported that the lower left atrial strain independently predicted occult paroxysmal AFib regardless of age in a small sample of patients with cryptogenic stroke.⁷⁶

Ventricular akinesia

In patients with ischemic cerebrovascular accidents, assessing LV wall motion is crucial because ventricular akinesia or dyskinesia may result in thrombus formation. The TTE is the gold standard technique for evaluating regional and global LV function and for detecting thrombi in the LV chamber with a 95% sensitivity and 85–90% specificity.⁷⁷ A LV thrombus is defined as a discrete echo dense mass in the LV with defined margins that are distinct from the endocardium and are observed throughout the systole and the diastole in an area of abnormal wall motility (hypokinetic or akinetic).³ The thrombus should be seen in at least two orthogonal views (apical and short axis); care must be taken to rule out artifacts, including false tendons or trabeculae.^{78,79} In some cases, the LV apex cannot be well visualized and the diagnosis of apical thrombus cannot be easily made. In this case, echocontrast ultrasound agent injected intravenously might enhance the accuracy in the thrombus detection, allows more precise quantification of the LV volume and reduces both intraobserver and interobserver variability.^{80,81}

During TTE it is essential also to rule out the presence of LV aneurysm defined as a localized area of akinesia or dyskinesia deforming the LV chamber during both systole and diastole, often in the presence of a thin myocardial wall.³ It usually occurs as a complication of MI and it may predispose to thrombus formation.

At TTE, several characteristics of the thrombus, useful for the clinical management, can be defined. LV thrombus may be flat and parallel to the endocardial surface (mural thrombus), or protruding into the LV cavity with more than one surface exposed to the blood (protruding thrombus). The size of the thrombus should also be

assessed measuring the maximal thickness perpendicular to the myocardium, from the epicardial interface to the inner-most border of the thrombus–blood interface.³ LV thrombi can be mobile, with an independent motion of a portion of the thrombus, or fixed along the LV wall with minor embolic risk. Color Doppler imaging may be helpful to differentiate the two types of thrombi.³

Severe aortic atheroma plaque

The evaluation of the aortic arch is extremely important in the setting of an acute cerebrovascular event because it might represent a possible source of embolism. TEE represents the best ultrasound technique for the diagnosis; however, TTE may be able to precisely identify an aortic atheroma by the suprasternal view.^{82–84} Moreover, TTE provides complementary views of some regions, which may be blinded on TEE, that is the distal ascending aorta and the proximal arch. Indeed, TTE with adequate image quality achieves the diagnosis in 84% of cases.⁸⁵ Nevertheless, most cardiologists do not routinely perform aortic arch analysis during TTE, despite the recommendations of both the American and European Society of Echocardiography.^{3,4}

Aortic atheromas may be classified according to the echocardiographic morphology of the plaque^{86,87} in two major types: simple (thickening aortic intima <4 mm) and complex (presence of ulceration, calcification, lumen restriction and mobile components). As mentioned above and according to the French Study of Aortic Plaques in Stroke, only plaques thicker than at least 4 mm result in increased embolic risk,⁴¹ making this finding very important and helpful for the clinical management of patients with ischemic stroke. In patients with ischemic stroke of undetermined origin, TEE is mandatory when image quality is inadequate, but it can be also performed to better define the plaque characteristics.

The development of electron-beam CT to quantify coronary artery calcification and coronary atherosclerotic plaque burden allowed similar progress on the quantification of aortic wall calcifications by conventional CT. Unlike coronary arteries, the size of the aorta is larger, making the quantification of noncalcified plaques easier, particularly with contrast-enhanced CT. This approach has been proposed as a valuable noninvasive method for following the evolution of atherosclerotic disease. Similar to CT, MRI can show the complete aorta (including the blind spots on TEE) and assesses the disease in the great vessels. In addition to identifying the morphologic features of atheromas, MRI evaluates the contrast between different types of tissues and may define the histologic components of the atherosclerotic plaques.⁸⁸

Cardiac shunt

PFO detection is relevant in patients younger than 55 years old with cryptogenic stroke,^{89,90} in absence of other more likely causes, such as atherosclerotic disease

or paroxysmal AFib. Transcranial Doppler imaging is usually performed to identify PFO by detecting micro-bubbles in the middle cerebral artery following intravenous fluid injection. A recent meta-analysis has shown that this technique is more sensitive but less specific compared with TTE.⁹¹

Contrast-enhanced TEE provides unparalleled visualization of the interatrial septum and other relevant structures and may show the shunt by itself.⁹² Nevertheless, a meta-analysis on the accuracy of TEE in PFO diagnosis compared with autopsy, cardiac surgery and catheterization yielded a weighted sensitivity of only 89%, probably due to the inability to perform an adequate Valsalva maneuver during TEE.⁹³ Yet, TEE is necessary to characterize the PFO and to stratify the risk in the subsequent diagnostic workup.

At present, grounded on the accrued low-quality evidence, no technique can be considered the gold standard and, in most cases, the precise diagnosis of PFO needs the combination of different approaches.⁹² As first-line, investigations should minimize the false negative individuals, and recently it has proposed the following diagnostic algorithm⁹²: the first-line examinations should be contrast-enhanced TTE or, if TTE is negative or equivocal, contrast-enhanced transcranial Doppler. If these screening examinations are negative, no further investigations are required; if these exams are positive, a contrast-enhanced TEE should be performed.

Presence of ASA at TTE considerably increases the likelihood of PFO.⁹⁴ ASA is diagnosed in case of fixed displacement or mobile excursion of the fossa ovalis region of the atrial septum towards the right atrium (RA) or LA, or both, exceeding 10 mm from the midline.³ It seems that ASA acts like a net that captures thrombi directing them through the PFO, and, therefore, increasing the risk of stroke.^{49,50}

After the morphological examination, the color Doppler is helpful to identify the direction of the shunt (right-to-left versus left-to-right). If routine color Doppler imaging fails to detect the shunt across the PFO, a shaken normal 0.9% saline solution contrast study may be performed.⁹⁵ The shunt is confirmed when an intravenous micro-bubble passing from the RA into the LA is directly observed within three cardiac cycles after the complete opacification of the RA.⁹⁶ To increase the right atrial pressure to enhance the diagnostic accuracy, provocative maneuvers such as cough and Valsalva maneuvers may be undertaken. It is also important to identify possible deviation of the interatrial septum towards the left atrial side, confirming elevated atrial pressure. Shunt quantification is difficult; however, a large shunt is defined if more than 20 bubbles cross the PFO from the right side to the LA either spontaneously or after the Valsalva maneuver.⁴ If the stirred saline contrast is noted after five cardiac cycles after complete opacification of the RA,

pulmonary arteriovenous malformations should be considered.⁹⁷ Finally, when PFO is diagnosed during TTE or transcranial Doppler, it is necessary to perform a TEE to confirm the presence of the PFO and to exclude other possible shunts.

The role of transesophageal echocardiography in the embolic stroke of undetermined source

TEE plays an important role in the setting of ESUS⁹⁸ when the quality of TTE is poor depending on the patient's body habitus, size of intercostal spaces, presence of chest deformities and lung diseases. The TEE probe allows a close proximity between the transducer and intracardiac structures, in particular the most posterior ones, providing images with higher resolution and revealing findings possibly associated with a cardiac or aortic source of embolism.⁴ From a technical point of view, if TTE is the most powerful instrument to visualize anterior cardiac structures using lower-frequency probes, TEE, exploiting the use of higher-frequency probes, maximizes the visualization of posterior and valvular structures as well as the thoracic aorta. Nevertheless, TEE is a semi-invasive procedure burdened by possible serious complications and the indications for TEE should follow precise and shared guidelines.⁹⁹

The use of TEE to image occult structural lesions possibly associated with ESUS includes the evaluation of LAA, aortic arch/proximal aorta atheroma, intracardiac masses and valvular heart diseases.

The visualization of LAA is obtained from the midesophageal four-chamber view at a transducer angle of approximately 90 degrees with the probe tip anteфлекed. The possibility to apply simultaneous biplane imaging of an orthogonal view might be helpful for excluding thrombi in patients with paroxysmal AFib or other undetected atrial arrhythmias. The presence of prominent pectinate muscles as well as trabeculations in the LAA could hinder definite exclusion of thrombus. The use of spectral Doppler evaluation of emptying velocities helps in determining stasis in the appendage: velocities less than 0.20 cm/s are suggestive of a lower flow state. Furthermore, the presence of spontaneous echo contrast together with low LAA flow is associated with paroxysmal AFib and should be looked at when evaluating patients with ESUS.¹⁰⁰ If TEE evaluation of LAA is equivocal the use of micro-bubble transpulmonary echocontrast could be helpful.

PFO can be visualized with 2-dimensional and 3-dimensional TEE from multiple views, even though the midesophageal bicaval view at 110 degrees may be considered the section of choice during saline contrast study.¹⁰¹ As already said, PFO is presumed when agitated saline contrast is noted in the LA within three cardiac cycles after complete opacification of the RA either at rest

or with provocative manoeuvres. Given the possible false positive results, that is pulmonary arteriovenous malformations, the most accurate way to exclude a PFO with TEE is the direct visualization of shunting through color Doppler evaluation and the frequently associated interatrial septal aneurysm or the transcranial Doppler ultrasonography with agitated saline bubble study.¹⁰²

Valvular heart disease, such as infective endocarditis, nonbacterial thrombotic endocarditis, valvular papillary fibroelastoma, mitral annular calcification and prosthetic valve endocarditis, have been associated with embolism.⁴ TEE provides improved image quality for an en face view of cardiac valves and it is particularly useful for small vegetations (<2–3 mm). TEE is recommended as the initial diagnostic test in all patients with suspected prosthetic valve infective endocarditis. Apart from infective endocarditis and prosthetic valve dysfunction, which are characterized by a precise clinical setting, other examples of TEE usefulness are nonbacterial endocarditis or Libman–Sacks endocarditis. Nonbacterial endocarditis can be clinically asymptomatic until systemic embolization occurs. It can be found in 43% of patients with systemic lupus erythematosus; the verrucae are composed of granular materials containing immune complexes and platelet thrombi. In contrast with infective endocarditis they appear more rounded, not associated with valvular destruction and affect typically the free edges of the mitral leaflets. Other forms of marantic endocarditis are associated with malignancy (i.e. solid metastatic carcinomas).¹⁰³ The association between embolism and the presence of valvular strands or Lambl's excrescences is not clear and conflicting results have been found in the literature.¹⁰⁴

Primitive cardiac tumors, even though usually benign, may have a malignant clinical course due to their high embolic potential. The two most common primary cardiac tumors with embolic potential are myxoma and papillary fibroelastoma. Myxomas are partially vascularized and may, therefore, be partly opacified on microbubble contrast imaging, differently from thrombi and malignant tumors. Papillary fibroelastoma is the second most common primary cardiac tumor in adults and is usually located on cardiac valves: on the aortic side of the aortic valve and on the ventricular side of the mitral valve (versus infective endocarditis). The sensitivity of TEE in the detection of papillary fibroelastoma is higher than TTE's.⁴

Atherosclerotic plaque can be easily detected by TEE, which is the most sensitive and used technique to examine the proximal portion of the aorta (proximal to the origin of the left subclavian artery) due to the absence of interposed tissue between the aorta and the esophagus. The identification of superimposed thrombus or ulceration gives TEE a sensitivity of respectively 91% and 75%.¹⁰⁵

Conclusion

Nowadays, a quarter of ischemic strokes after a complete diagnostic workup are still labeled as of undetermined etiopathogenesis at discharge with a significant mortality rate.¹⁰⁶ Echocardiographic evaluation is crucial in the early phase of ESUS to identify the origin of the embolic stroke or to detect indirect clues of a possible cardiac embolism. By diagnosing the cardiac source of embolism as soon as possible, echocardiography may be helpful in preventing recurrences especially during the first week after an acute cerebrovascular event.

Acknowledgements

Conflicts of interest

There are no conflicts of interest.

References

- Rothwell PM, Coull AJ, Silver LE, et al. Population-based study of event-rate, incidence, case fatality, and mortality for all acute vascular events in all arterial territories (Oxford Vascular Study). *Lancet* 2005; **366**:1773–1783.
- Cardiogenic brain embolism: the second report of the cerebral embolism task force. *Arch Neurol* 1989; **46**:727–743.
- Pepi M, Evangelista A, Nihoyannopoulos P, et al. Recommendations for echocardiography use in the diagnosis and management of cardiac sources of embolism: European Association of Echocardiography (EAE) (a registered branch of the ESC). *Eur J Echocardiogr* 2010; **11**:461–476.
- Saric M, Armour AC, Arnaout MS, et al. Guidelines for the use of echocardiography in the evaluation of a cardiac source of embolism. *J Am Soc Echocardiogr* 2016; **29**:1–42.
- Ntaios G, Michel P. Temporal distribution and magnitude of the vulnerability period around stroke depend on stroke subtype. *Cerebrovasc Dis* 2011; **32**:246–253.
- Hudorovic N, Vicio-Hudorovic V. eComment. Costs, nursing administrators and predictors of intensive care unit length of stay. *Interact Cardiovasc Thorac Surg* 2012; **15**:833.
- Cocho D, Bravo Y, Leta R, et al. Transthoracic echocardiography in stroke performed by neurologist: pilot study. *Neurologia* 2007; **22**:420–425.
- Pagola J, González-Alujas T, Muchada M, et al. Stroke echocan protocol: a fast and accurate pathway to diagnose embolic stroke. *J Neuroimaging* 2015; **25**:365–369.
- Ramirez-Lassepas M, Cipolle RJ, Bjork RJ, et al. Can embolic stroke be diagnosed on the basis of neurologic clinical criteria? *Arch Neurol* 1987; **44**:87–89.
- Kraus JA, Berlitz P. Cerebral embolism and epileptic seizures: the role of the embolic source. *Acta Neurol Scand* 1998; **97**:154–159.
- Minematsu K, Yamaguchi T, Omae T. 'Spectacular shrinking deficit': rapid recovery from major hemispheric syndrome by migration of an embolus. *Neurology* 1992; **42**:157–162.
- Gacs G, Merei FT, Bodosi M. Balloon catheter as a model of cerebral emboli in humans. *Stroke* 1982; **13**:39–42.
- Timsit SG, Sacco RL, Mohr JP, et al. Brain infarction severity differs according to cardiac or arterial embolic source. *Neurology* 1993; **43**:728–733.
- Ringelstein EB, Koschorke S, Holling A, Thron A, Lambert H, Minale C. Computed tomographic patterns of proven embolic brain infarctions. *Ann Neurol* 1989; **26**:759–765.
- Bogousslavsky J, Bernasconi A, Kumral E. Acute multiple infarction involving the anterior circulation. *Arch Neurol* 1996; **53**:50–57.
- Hart RG, Easton JD. Hemorrhagic infarcts. *Stroke* 1986; **17**:586–589.
- Go AS, Hylek EM, Phillips KA, et al. Prevalence of diagnosed atrial fibrillation in adults: national implications for rhythm management and stroke prevention: the AnTicoagulation and Risk Factors in Atrial Fibrillation (ATRIA) Study. *JAMA* 2001; **285**:2370–2375.
- Manning W. Cardiac sources of embolism: pathophysiology and identification. In: Caplan LR, Manning W, editors. *Brain embolism*. New York: Informa Healthcare; 2006. pp. 161–186.
- Chiarella F, Santoro E, Domenicucci S, Maggioni A, Vecchio C. Predischarge two-dimensional echocardiographic evaluation of thrombosis after acute myocardial infarction in the GISSI-3 study. *Am J Cardiol* 1998; **81**:822–827.

- 20 Solheim S, Seljeflot I, Lunde K, *et al.* Frequency of left ventricular thrombus in patients with anterior wall acute myocardial infarction treated with percutaneous coronary intervention and dual antiplatelet therapy. *Am J Cardiol* 2010; **106**:1197–1200.
- 21 Nihoyannopoulos P, Smith GC, Maseri A, Foale RA. The natural history of left ventricular thrombus in myocardial infarction: a rationale support of masterly inactivity. *J Am Coll Cardiol* 1989; **14**:903–911.
- 22 Lapeyre AC 3rd, Steele PM, Kazmier FJ, Chesebro JH, Vlietstra RE, Fuster V. Systemic embolism in chronic left ventricular aneurysm: Incidence and the role of anticoagulation. *J Am Coll Cardiol* 1985; **6**:534–538.
- 23 Asinger RW, Mikell FL, Elsparger J, Hodges M. Incidence of left ventricular thrombosis after acute transmural infarction: serial evaluation by two-dimensional echocardiography. *N Engl J Med* 1981; **305**:297–302.
- 24 Meltzer RS, Visser CA, Fuster V. Intracardiac thrombi and systemic embolization. *Ann Intern Med* 1986; **104**:689–698.
- 25 Johannessen KA, Nordrehaug JE, von der Lippe G, Vollset SE. Risk factors for embolization in patients with left ventricular acute myocardial infarction. *Br Heart J* 1988; **60**:104–110.
- 26 Loh E, Sutton M, Wun CC, *et al.* Ventricular dysfunction and the risk of stroke after myocardial infarction. *N Engl J Med* 1997; **336**:251–257.
- 27 Ramasamy S, Yaghi S, Salehi Omran S, *et al.* Association between left ventricular ejection fraction, wall motion abnormality, and embolic stroke of undetermined source. *J Am Heart Assoc* 2019; **8**:e011593.
- 28 Choi JY, Cha J, Jung JM, *et al.* Left ventricular wall motion abnormalities are associated with stroke recurrence. *Neurology* 2017; **88**:586–594.
- 29 Koniaris LS, Goldhaber SZ. Anticoagulation in dilated cardiomyopathy. *J Am Coll Cardiol* 1998; **31**:745–748.
- 30 Caplan L. *Caplan's stroke a clinical approach*, 4th ed. Philadelphia, PA: Saunders Elsevier; 2009; 339.
- 31 Reynen K. Cardiac myxomas. *N Engl J Med* 1995; **333**:1610–1617.
- 32 Blondeau P. Primary cardiac tumors: French study of 533 cases. *Thorac Cardiovasc Surg* 1990; **38** (Suppl 2):192–195.
- 33 Levine HJ, Pauker SG, Eckman MH. Antithrombotic therapy in valvular heart disease. *Chest* 1995; **108** (4 Suppl):360S–370S.
- 34 Gohlke-Barwolf C, Acar J, Oakley C, *et al.* Guidelines for prevention of thromboembolic events in valvular heart disease: study group of the Working Group on Valvular Heart Disease of the European Society of Cardiology. *Eur Heart J* 1995; **16**:1320–1330.
- 35 Szekely P. Systemic embolism and anticoagulant prophylaxis in rheumatic heart disease. *Br Med J* 1964; **1**:1209–1212.
- 36 Daley R, Mattingly TW, Holt CL, Bland EF, White PD. Systemic arterial embolism in rheumatic heart disease. *Am Heart J* 1951; **42**:566–581.
- 37 Roudaut R, Serri K, Lafitte S. Thrombosis of prosthetic heart valves: diagnosis and therapeutic considerations. *Heart* 2007; **93**:137–142.
- 38 Tunich PA, Kronzon I. Atheromas of the thoracic aorta: clinical and therapeutic update. *J Am Coll Cardiol* 2000; **35**:545–554.
- 39 Ntaios G, Pearce LA, Meseguer E, *et al.* Aortic arch atherosclerosis in patients with embolic stroke of undetermined source: an exploratory analysis of the NAVIGATE ESUS trial. *Stroke* 2019; **50**:3184–3190.
- 40 Ueno Y, Tateishi Y, Dojiri R, *et al.* Large aortic arch plaques correlate with CHADS2 and CHA2DS2-VASc scores in cryptogenic stroke. *Atherosclerosis* 2019; **184**:181–186.
- 41 Amarenco P, Cohen A, Hommel M, Moulin T, Leys D, Bousser M-G. The French Study of Aortic Plaques in Stroke Group. Atherosclerotic disease of the aortic arch as a risk factor for recurrent ischemic stroke. *N Engl J Med* 1996; **334**:1216–1221.
- 42 Cohen A, Tzourio C, Bertrand B, Chauvel C, Bousser MG, Amarenco P, FAPS Investigators. French Study of Aortic Plaques in Stroke. Aortic plaque morphology and vascular events: a follow-up study in patients with ischemic stroke. *Circulation* 1997; **96**:3838–3841.
- 43 Amarenco P, Cohen A, Tzourio C. Atherosclerotic disease of the aortic arch as the risk of ischemic stroke. *N Engl J Med* 1994; **331**:1474–1479.
- 44 Capmany RP, Ibanez MO, Pesquer XJ. Complex atheromatosis of the aortic arch in cerebral infarction. *Curr Cardiol Rev* 2010; **3**:184–193.
- 45 Cui X, Li Y, Liu J, He S, Liu M. Aortic arch atheroma and the risk of stroke: a meta-analysis. *J Evid Based Med* 2014; **7**:185–191.
- 46 Di Salvo G, Habib G, Pergola V, *et al.* Echocardiography predicts embolic events in infective endocarditis. *J Am Coll Cardiol* 2001; **37**:1069–1076.
- 47 Thuny F, Di Salvo G, Belliard O, *et al.* Risk of embolism and death in infective endocarditis: prognostic value of echocardiography: a prospective multicenter study. *Circulation* 2005; **112**:744–754.
- 48 Mojadini MK, Christia P, Salamon J, *et al.* Patent foramen ovale: unanswered questions. *Eur J Intern Med* 2015; **26**:743–751.
- 49 Messé SR, Silverman IE, Kizer JR, *et al.* Practice parameter: recurrent stroke with patent foramen ovale and atrial septal aneurysm: report of the Quality Standards Subcommittee of the American Academy of Neurology. *Neurology* 2004; **62**:1042–1050.
- 50 Larrue V, Berhoun N, Massabau P, *et al.* Etiologic investigation of ischemic stroke in young adult. *Neurology* 2011; **76**:1983–1988.
- 51 Schuchlenz HW, Weihs W, Horner S, Quehenberger F. The association between the diameter of a patent foramen ovale and the risk of embolic cerebrovascular events. *Am J Med* 2000; **109**:456–462.
- 52 Adams HP Jr, Bendixen BH, Kappelle LJ, *et al.* Classification of subtype of acute ischemic stroke: definitions for use in a multicenter clinical trial. TOAST. Trial of Org 10172 in Acute Stroke Treatment. *Stroke* 1993; **24**:35–41.
- 53 Hart RG, Diener HC, Coutts SB, *et al.* Embolic strokes of undetermined source: the case for a new clinical construct. *Lancet Neurol* 2014; **13**:429–438.
- 54 Sacco RL, Prabhakaran S, Thompson JLP, *et al.* WARSS Investigators. Comparison of warfarin versus aspirin for the prevention of recurrent stroke or death: subgroup analyses from the Warfarin-Aspirin Recurrent Stroke Study. *Cerebrovasc Dis* 2006; **22**:4–12.
- 55 Halkes PH, van Gijn J, Kappelle LJ, Koudstaal PJ, Algra A, ESPRIT Study Group. Medium intensity oral anticoagulants versus aspirin after cerebral ischaemia of arterial origin (ESPRIT): a randomised controlled trial. *Lancet Neurol* 2007; **6**:115–124.
- 56 Hart RG, Sharma M, Mundt H, *et al.* Rivaroxaban for stroke prevention after embolic stroke of undetermined source. *N Engl J Med* 2018; **378**:2191–2201.
- 57 Diener HC, Easton JD, Granger CB, *et al.* RE-SPECT ESUS Investigators. Design of randomized, double-blind, evaluation in secondary stroke prevention comparing the efficacy and safety of the oral thrombin inhibitor dabigatran etexilate vs. acetylsalicylic acid in patients with embolic stroke of undetermined source (RE-SPECT ESUS). *Int J Stroke* 2015; **10**:1309–1312.
- 58 Geisler T, Poli S, Meisner C, *et al.* Apixaban for treatment of embolic stroke of undetermined source (ATTICUS randomized trial): rationale and study design. *Int J Stroke* 2017; **12**:985–990.
- 59 Diener HC, Bernstein R, Hart R. Secondary stroke prevention in cryptogenic stroke and embolic stroke of undetermined source (ESUS). *Curr Neurol Neurosci Rep* 2017; **17**:64.
- 60 Tsang TS, Abhayaratna WP, Barnes ME, *et al.* Prediction of cardiovascular outcomes with left atrial size: is volume superior to area or diameter? *J Am Coll Cardiol* 2006; **47**:1018–1023.
- 61 Rosca M, Lancellotti P, Popescu BA, Pierard LA. Left atrial function: pathophysiology, echocardiographic assessment, and clinical applications. *Heart* 2011; **97**:1982–1989.
- 62 Barnes ME, Miyasaka Y, Seward JB, *et al.* Left atrial volume in the prediction of first ischemic stroke in an elderly cohort without atrial fibrillation. *Mayo Clin Proc* 2004; **79**:1008–1014.
- 63 Benjamin EJ, D'Agostino RB, Belanger AJ, Wolf PA, Levy D. Left atrial size and the risk of stroke and death—the Framingham Heart Study. *Circulation* 1995; **92**:835–841.
- 64 Jordan K, Yaghi S, Poppas A, *et al.* Left atrial volume index is associated with cardioembolic stroke and atrial fibrillation detection after embolic stroke of undetermined source. *Stroke* 2019; **50**:1997–2001.
- 65 Lang RM, Badano LP, Mor-Avi V, *et al.* Recommendations for cardiac chamber quantification by echocardiography in adults: an update from the American Society of Echocardiography and the European Association of Cardiovascular Imaging. *Eur Heart J Cardiovasc Imaging* 2015; **16**:233–270.
- 66 Benjamin EJ, Wolf PA, D'Agostino RB, Silbershatz H, Kannel WB, Levy D. Impact of atrial fibrillation on the risk of death: the Framingham Heart Study. *Circulation* 1998; **98**:946–952.
- 67 Takada T, Yasaka M, Nagatsuka K, Minematsu K, Yamaguchi T. Blood flow in the left atrial appendage and embolic stroke in nonvalvular atrial fibrillation. *Eur Neurol* 2001; **46**:148–152.
- 68 Garcia-Fernandez MA, Torrecilla EG, San Roman D, *et al.* Left atrial appendage Doppler flow patterns: implications on thrombus formation. *Am Heart J* 1992; **124**:955–961.
- 69 De Luca I, Colonna P, Sorino M, Del Salvatore B, De Luca L. New non-dimensional transthoracic echocardiographic sign of left atrial appendage function. *J Am Soc Echocardiogr* 2007; **20**:324–332.
- 70 Wai SH, Kyu K, Galupo MJ, *et al.* Assessment of left atrial appendage function by transthoracic pulsed Doppler echocardiography: comparing against transesophageal interrogation and predicting echocardiographic risk factors for stroke. *Echocardiography* 2017; **34**:1478–1485.
- 71 Verhorst PM, Kamp O, Visser CA, Verheugt FW. Left atrial appendage flow velocity assessment using transesophageal echocardiography in nonrheumatic atrial fibrillation and systemic embolism. *Am J Cardiol* 1993; **71**:192–196.
- 72 Kamp O, Verhorst PM, Welling RC, Visser CA. Importance of left atrial appendage flow as a predictor of thromboembolic events in patients with atrial fibrillation. *Eur Heart J* 1999; **20**:979–985.

- 73 Sparks PB, Mond HG, Vohra JK, Yapanis AG, Grigg LE, Kalman JM. Mechanical remodeling of the left atrium after loss of atrioventricular synchrony: a long-term study in humans. *Circulation* 1999; **100**: 1714–1721.
- 74 Teske AJ, De Boeck BW, Melman PG, Sieswerda GT, Doevendans PA, Cramer MJ. Echocardiographic quantification of myocardial function using tissue deformation imaging, a guide to image acquisition and analysis using tissue Doppler and speckle tracking. *Cardiovasc Ultrasound* 2007; **5**:27.
- 75 Azemi T, Rabdiya VM, Ayirala SR, McCullough LD, Silverman DI. Left atrial strain is reduced in patients with atrial fibrillation, stroke or TIA, and low risk CHADS(2) scores. *J Am Soc Echocardiogr* 2012; **25**:1327–1332.
- 76 Pagola J, González-Alujas T, Flores A, *et al.* Left atrial strain is a surrogate marker for detection of atrial fibrillation in cryptogenic strokes. *Stroke* 2014; **45**:e164–e166.
- 77 Jugdutt BI, Sivaram CA. Prospective two-dimensional echocardiographic evaluation of left ventricular thromboembolism after acute myocardial infarction. *J Am Coll Cardiol* 1989; **13**:554–564.
- 78 Srichai MB, Junor C, Rodriguez LL, *et al.* Clinical, imaging, and pathological characteristics of left ventricular thrombus: a comparison of contrast-enhanced magnetic resonance imaging, transthoracic echocardiography, and transesophageal echocardiography with surgical or pathological validation. *Am Heart J* 2006; **152**:75–84.
- 79 van Dantzig JM, Delemarre BJ, Bot H, Visser CA. Left ventricular thrombus in acute myocardial infarction. *Eur Heart J* 1996; **17**:1640–1645.
- 80 Senior R, Becher H, Monaghan M, *et al.* Contrast echocardiography: evidence-based recommendations by European Association of Echocardiography. *Eur J Echocardiogr* 2009; **10**:194–212.
- 81 Kurt M, Shaikh KA, Peterson L, *et al.* Impact of contrast echocardiography on evaluation of ventricular function and clinical management in a large prospective cohort. *J Am Coll Cardiol* 2009; **53**:802–810.
- 82 Weinberger J, Azhar S, Danis F, Hayes R, Goldman M. A new noninvasive technique for imaging atherosclerotic plaque in the aortic arch of stroke patients by transcutaneous real-time B-mode ultrasonography: an initial report. *Stroke* 1998; **29**:673–676.
- 83 Van der Loo B, Oechslin E, Jenni R, Cohen A, Amarencu P. Assessment of atherosclerotic plaques of the aortic arch. *N Engl J Med* 2002; **347**:949–953.
- 84 Hussein A, Hilal D, Hamoui O, *et al.* Value of aortic arch analysis during routine transthoracic echocardiography in adults. *Eur J Echocardiogr* 2009; **10**:625–629.
- 85 Schwammenthal E, Schwammenthal Y, Tanne D, *et al.* Transcutaneous detection of aortic arch atheromas by suprasternal harmonic imaging. *J Am Coll Cardiol* 2002; **39**:1127–1132.
- 86 Amarencu P. Cryptogenic stroke, aortic arch atheroma, patent foramen ovale, and the risk of stroke. *Cerebrovasc Dis* 2005; **20** (Suppl 2): 68–74.
- 87 Khathibzadeh M, Mitusch R, Stierle U, Gromoll B, Sheikhzadeh A. Aortic atherosclerotic plaques as a source of systemic embolism. *J Am Coll Cardiol* 1996; **27**:664–669.
- 88 Tunick PA, Krinsky GA, Lee VS, Kronzon I. Diagnostic imaging of thoracic aortic atherosclerosis. *AJR Am J Roentgenol* 2000; **174**:1119–1125.
- 89 Mazzucco S, Bovi P, Carletti M, *et al.* A model of multidisciplinary approach to the diagnosis and treatment of young patients with cryptogenic stroke and patent foramen ovale. *Cardiol Young* 2012; **22**:327–334.
- 90 Danese A, Stegagno C, Tomelleri G, *et al.* Clinical outcomes of secondary prevention strategies for young patients with cryptogenic stroke and patent foramen ovale. *Acta Cardiol* 2017; **72**:410–418.
- 91 Katsanos AH, Psaltopoulou T, Sergentanis TN, *et al.* Transcranial Doppler versus transthoracic echocardiography for the detection of patent foramen ovale in patients with cryptogenic cerebral ischemia: a systematic review and diagnostic test accuracy meta-analysis. *Ann Neurol* 2016; **79**:625–635.
- 92 Pristipino C, Sievert H, D'Ascenzo F, *et al.* European position paper on the management of patients with patent foramen ovale: general approach and left circulation thromboembolism. *Eurointervention* 2019; **14**:1389–1402.
- 93 Mojadidi MK, Bogush N, Caceres JD, Msaouel P, Tobis JM. Diagnostic accuracy of transesophageal echocardiogram for the detection of patent foramen ovale: a meta-analysis. *Echocardiography* 2014; **31**:752–758.
- 94 Overell JR, Bone I, Lees KR. Interatrial septal abnormalities and stroke: a meta analysis of case-control studies. *Neurology* 2000; **55**:1172–1179.
- 95 Porter TR, Abdelmoneim S, Belcik JT, *et al.* Guidelines for the cardiac sonographer in the performance of contrast echocardiography: a focused update from the American Society of Echocardiography. *J Am Soc Echocardiogr* 2014; **27**:797–810.
- 96 Pinto FJ. When and how to diagnose patent foramen ovale. should it always be repaired? *Heart* 2005; **91**:438–440.
- 97 Van Camp G, Schulze D, Cosyns B, Vandembosche JL. Relation between patent foramen ovale and unexplained stroke. *Am J Cardiol* 1993; **71**:596–598.
- 98 Katsanos AH, Bhole R, Frogoudaki A, *et al.* The value of transesophageal echocardiography for embolic strokes of undetermined source. *Neurology* 2016; **87**:988–995.
- 99 Hahn RT, Abraham T, Adams MS, Bruce CJ, Glas KE, Lang RM. Guidelines for performing a comprehensive transesophageal echocardiographic examination: recommendations from the American Society of Echocardiography and the Society of Cardiovascular Anesthesiologists. *J Am Soc Echocardiogr* 2013; **26**:921–964.
- 100 Ohya Y, Osaki M, Fujimoto S, *et al.* Usefulness of transesophageal echocardiography for predicting covert paroxysmal atrial fibrillation in patients with embolic stroke of undetermined source. *Cerebrovasc Dis Extra* 2019; **9**:98–106.
- 101 Marriott K, Manins V, Forshaw A, Wright J, Pascoe R. Detection of right-to-left atrial communication using agitated saline contrast imaging: experience with 1162 patients and recommendations for echocardiography. *J Am Soc Echocardiogr* 2013; **26**:96–102.
- 102 Caputi L, Carriero MR, Falcone C, *et al.* Transcranial Doppler and transesophageal echocardiography: comparison of both techniques and prospective clinical relevance of transcranial Doppler in patent foramen ovale detection. *J Stroke Cerebrovasc Dis* 2009; **18**:343–348.
- 103 Reisner SA, Brenner B, Haim N, Edoute Y, Markiewicz W. Echocardiography in nonbacterial thrombotic endocarditis: from autopsy to clinical entity. *J Am Soc Echocardiogr* 2000; **13**:876–881.
- 104 Roldan CA, Shively BK, Crawford MH. Valve excrescences: prevalence, evolution and risk for cardioembolism. *J Am Coll Cardiol* 1997; **30**:1308–1314.
- 105 Vaduganathan P, Ewton A, Nagueh SF, Weilbaecher DG, Safi HJ, Zoghbi WA. Pathologic correlates of aortic plaques, thrombi and mobile 'aortic debris' imaged in vivo with transesophageal echocardiography. *J Am Coll Cardiol* 1997; **30**:357–363.
- 106 Nam HS, Kim HC, Kim YD, *et al.* Long-term mortality in patients with stroke of undetermined etiology. *Stroke* 2012; **43**:2948–2956.