

# Immediate reconstruction with implant post-mastectomy with prepectoral versus submuscular technique: experience of a public oncological treatment center

Pedro Lima Costa<sup>1</sup> , Yara Carolina Monte de Sena Rosa<sup>1</sup> , Gláucia Mesquita Cordeiro<sup>1</sup> , Ana Gabriela Caldas Oliveira<sup>2</sup> , Raquel Aranha Viegas<sup>1</sup> , José Pereira Guará<sup>1,2\*</sup> 

## ABSTRACT

**Introduction:** Reconstruction techniques after mammary adenectomy with implant placement in the prepectoral space without the use of cell dermal matrix have been attracting more interest recently. However, data on the risk of complications, especially in patients treated in Brazil by the Brazilian Unified Health System, are scarce. **Methods:** This is a retrospective cohort study on women who underwent mammary adenectomy and immediate reconstruction with implants in a public hospital in Brazil, with survival analysis for implant extrusion and its associated factors. **Results:** Prepectoral and submuscular implant-based reconstruction had similar clinical outcomes. High axillary involvement (four or more lymph nodes) was the only factor associated with implant extrusion, regardless of the implant reconstruction techniques used. **Conclusions:** Tumor burden might interfere with the immediate implant-based breast reconstruction.

**KEYWORDS:** breast cancer; breast implants; oncoplasty.

## INTRODUCTION

Breast cancer is the disease that most affects women in the world. About one million cases are diagnosed per year<sup>1</sup>. In Brazil, there are approximately 73,610 new cases per year, with an estimated risk of 73.61 cases per 100 thousand women<sup>2</sup>.

Breast cancer treatment is multimodal, encompassing systemic therapy (chemotherapy, endocrine therapy, immunotherapy, targeted therapies, etc.), surgery, and radiotherapy. However, the main therapeutic strategy for localized disease is surgical intervention<sup>3</sup>. Although radical and conservative surgeries have comparable survival rates, breast conservation combined with radiotherapy is the standard treatment<sup>3,4</sup>. Nevertheless, there are still classic indications for mastectomy: presence of previous thoracic radiation (due to previous breast cancer or Hodgkin's lymphoma), unfavorable tumor-breast relationship, extensive calcifications, multicentric disease, or in carriers of some high-penetrance genetic mutations<sup>4</sup>.

Mastectomies that spare the skin and the nipple-areola complex (adenomastectomy) provide better aesthetic results in immediate reconstructions and are oncologically safe. Silicone implants can be positioned in the submuscular plane or in the prepectoral space<sup>5,6</sup>.

The advantages of placing the implant in the submuscular plane are minimal visibility and palpability of the prosthesis, in addition to reduced rippling. As disadvantages, this technique can cause animation deformities, functional loss of the pectoralis major muscle, capsular contracture in varying degrees, and more postoperative pain<sup>5,6</sup>.

The reconstruction technique with implants in the prepectoral space was initially used in the 1980s, but was promptly rejected due to high complication rates<sup>5</sup>. However, as of 2015, the technique aroused increasing interest, as noted in the literature, mainly in Italian centers<sup>7</sup>.

The advent of dermal matrices has given rise to discussion regarding new possibilities for post-mastectomy reconstructions.

<sup>1</sup>Hospital do Câncer Aldenora Bello – São Luís (MA), Brazil.

<sup>2</sup>Universidade Federal do Maranhão – São Luís (MA), Brazil.

\*Corresponding author: drguara.masto@gmail.com

Conflict of interests: nothing to declare. Funding: none.

Received on: 02/26/2024. Accepted on: 07/03/2024.

Initially, they were used in a complementary way, covering the lower and lateral part, with the upper end sutured to the lower edge of the pectoralis major muscle, reducing the tension of the muscle bag. Nonetheless, this option maintained a potential risk for shoulder joint dysfunction and animation deformities associated with dissection of the pectoralis to create the muscle bag.

Aiming to remedy such damage, the prepectoral reconstruction technique with total or partial coverage of the implant by the acellular dermal matrix (ADM) has emerged. This consisted of including the prosthesis covered by the mesh in the glandular cavity itself, fixing it to the pectoralis major<sup>5</sup>.

Although the prepectoral technique using ADM has proven to be safe and advantageous in terms of reducing complications, the use of biological meshes or synthetic materials increases its costs<sup>8</sup>. This fact may limit its use by paying sources, especially in the Brazilian Unified Health System (SUS) scenario. Thus, prepectoral reconstruction without coverings emerged as an alternative, showing satisfactory initial results<sup>9,10</sup>.

This technique, however, may have disadvantages such as greater visibility and palpability of the implant, rippling, and implant extrusion. Some authors argue that undue weight and tension of the implant may put pressure on the mastectomy flap, preventing tissue perfusion<sup>11</sup>.

Currently, there has been interest in the results of prepectoral breast reconstruction techniques and their comparison with subpectoral ones. Therefore, in this study we aim to describe the profile of patients undergoing adenomastectomy followed by immediate reconstruction technique with pre- and subpectoral implants, without the use of dermal matrix, as well as factors associated with the risk of implant extrusion.

## METHODS

### Study design

This is a retrospective, observational, cohort, analytical study.

### Study location

High Complexity Oncology Assistance Center (*Centro de Assistncia de Alta Complexidade em Oncologia – CACON*) of the state of Maranho, Brazil, Hospital do Cncer Aldenora Bello [Aldenora Bello Cancer Hospital], maintained by the Fundao Antnio Dino [Antnio Dino Foundation], which assists patients from the Brazilian Unified Health System (SUS), health insurance plans, and private individuals.

### Inclusion criteria

Women who underwent skin-sparing mastectomy or skin- and nipple-sparing mastectomy followed by immediate single-stage reconstruction with silicone implants, between January 2021 and December 2022, treated exclusively by the SUS.

### Exclusion criteria

Women who underwent immediate reconstruction, using myocutaneous flaps, fat grafting, or who had an unviable area of the skin flap.

### Sampling method

The sample was obtained by convenience within the proposed period, with data collection after approval by the research ethics committee, through the analysis of electronic and physical medical records, which took place from March to July 2023.

### Description of surgical technique

The procedures were performed by five mastologists from this oncology reference unit, and the surgical technique was defined individually. Based on the indication profile for each technique, the sample was distributed between the prepectoral reconstruction and subpectoral reconstruction subgroups.

In the prepectoral technique, the anatomical limits were previously demarcated. The incision in the lateral third of the inframammary fold up to the muscular plane and then the dissection of the subglandular space up to signaled limits with preservation of the fascia of the pectoralis major muscle. Subsequently, the anterior glandular surface was dissected, preserving the skin flap and subcutaneous cellular tissue.

Biopsies of the retroareolar region were performed intraoperatively to rule out neoplastic involvement of the papilla. After checking hemostasis, the pocket was washed and the microtextured round silicone prosthesis was inserted, the size defined according to anatomical measurements and testing by placing molds.

Subpectoral reconstructions had different incisions according to the assessment of the attending mastologist. Some of the patients had large breasts with increased ptosis due to significant skin sagging. In these cases, a reduction mammoplasty-type incision with excision of the nipple-areola complex (NAC) was chosen, resulting in an inverted T-type scar, or a wedge incision to resect the NAC and excess skin in patients with signs of nipple-areola involvement. In the others, a periareolar or radial incision was chosen. In all cases, the gland was carefully dissected with the care already reported in the previous technique. Subsequently, the submuscular pocket was made by elevating the pectoralis major muscles and the fascia of the serratus anterior. Finally, the implant was included in this space and, subsequently, partial synthesis of the access to the pocket was performed to avoid lateral migration of the prosthesis.

In both techniques, the pocket was washed and the microtextured round silicone prosthesis was inserted, the size defined according to anatomical measurements and testing by placing molds.

### Study variables

The numerical variables are: age (years), body mass index (BMI), prosthesis size (cc), breast weight (g), surgery time (minutes), and time until implant extrusion (days).

The categorical variables are: age group, BMI category, smoking habit, clinical staging (TNM), type of surgery, laterality, type of incision, histology, histologic grade, immunohistochemical profile (IHC), focality, assessment of margin involvement, type of axillary surgery, number of dissected lymph nodes, number of involved lymph nodes, contralateral breast symmetrization, adjuvant radiotherapy, neoadjuvant chemotherapy (CT), implant extrusion, and staff (anonymized by the letters A to E).

## Statistical analysis

In the descriptive analysis, categorical variables are presented by frequencies and numerical variables by absolute numbers, medians, and interquartile ranges.

In the univariate analysis, Fisher's exact or Wilcoxon tests were used to associate the classification variables with the type of reconstruction technique used (prepectoral or subpectoral) and with the implant extrusion event (yes and no).

The logrank test was used to measure the difference in implant extrusion-free survival curves for each variable.

In the Cox survival model, the binary qualitative dependent variable used was the occurrence of extrusion: yes or no. The independent variables included were selected based on clinical criteria endorsed in the literature as factors associated with post-breast surgery complications.

## Ethical aspects

This research was approved by the Research Ethics Committee under the CAAE (Certificate of Presentation for Ethical Consideration) consubstantiated opinion number: 69155623.9.0000.8907.

## RESULTS

The study included 61 women, five of whom underwent bilateral mastectomies, one for bilateral breast cancer (synchronous tumor), and the others for risk reduction in the contralateral breast, totaling 66 mastectomies.

In Table 1 we describe the characterization of the sample stratified by surgical technique. This is a sample of young women, most of whom were over 45 years old, overweight/obese, who underwent surgery for stage II and III breast cancer, with invasive tumors of intermediate histologic grade, and a positive immunohistochemical profile of hormone receptors without overexpression of the HER-2 protein. Most tumors were unifocal, achieving free margin status at surgery. Regarding the axillary approach, sentinel lymph node biopsy (SLNB) was the most frequently performed procedure, most had up to four lymph nodes dissected and only 4.5% of the sample showed involvement of more than four lymph nodes. Most women underwent neoadjuvant chemotherapy and a smaller proportion required adjuvant radiotherapy.

In the analysis by subgroups, as shown in Table 1, the majority of patients underwent prepectoral reconstruction without

the use of acellular dermal matrix (55%). Patients in this subgroup had an inframammary fold with the incision of choice and had lower values of BMI, breast weight, prosthesis size, and surgery time, with a statistically significant difference ( $p < 0.05$ ) in all these variables. The proportion of implant extrusion was similar in the prepectoral and submuscular techniques; however, we verified a tendency in the prepectoral group toward later extrusion (median of 180 days) in relation to the group with prepectoral reconstruction (median of 48.5 days), but this relationship was not statistically relevant ( $p = 0.066$ ). In the other variables analyzed, we found no statistically relevant difference between the groups.

In Table 2 we present the univariate analysis data of the sample stratified by the outcome extrusion versus no implant extrusion. We can observe that only the variables type of axillary surgery and number of involved lymph nodes showed statistical difference between the subgroups.

In Figure 1 we present the curves for implant loss-free survival analysis. Only patients with massive axillary involvement, i.e., four or more involved lymph nodes, were associated with the risk of implant loss (logrank  $p < 0.05$ ).

In Table 3 we show the Cox survival model, whose dependent variable is implant extrusion. In the model, it was possible to verify that only the degree of axillary involvement (four or more involved lymph nodes) was associated with an increased risk of implant extrusion.

## DISCUSSION

Recently, skin-sparing mastectomies have been widely used worldwide for the treatment of breast cancer patients, recognized for the impact of breast reconstruction on the quality of life of female cancer survivors<sup>5</sup>.

For decades, reconstruction with a submuscular prosthesis was considered the most viable<sup>7-9</sup>. The first reports of the prepectoral technique date back to the 1970s, when it was strongly associated with the occurrence of implant loss, capsular contracture, and flap necrosis<sup>12,13</sup>. In recent years, however, its improvement has led to new discussions on the subject, as its application has less relation to postoperative pain and there are no repercussions on the functionality of the pectoralis major muscle, in addition to the techniques having comparable complication rates<sup>8,14-16</sup>.

In this study, acellular dermal matrix or similar material was not used to cover the implant in any of the reconstruction subgroups, considering that there is already research data that supports such practice, demonstrating that there is no increase in the complication rate, in addition to reducing costs and surgery time<sup>8,9,16</sup>. The implant loss rate (12%) in the general population of this study is compatible with that observed in other publications and does not present a statistically significant difference between the subgroups of each technique ( $p = 0.3$ )<sup>15-20</sup>.

**Table 1.** Epidemiological and clinical characteristics stratified by surgical reconstruction technique used.

Variables	Total n=66* (%)	Prepectoral n=36* (%)	Subpectoral n=30* (%)	p-value†
Age (years)	48 (41–53)	48 (41–54)	48 (44–52)	0.7
Age group (years)				
≤45	28 (42)	15 (42)	13 (43)	0.9
>45	38 (58)	21 (58)	17 (57)	
BMI (kg/m <sup>2</sup> )	25.8 (23.7–27.9)	24.5 (22.2–26.8)	27.0 (25.1–28.8)	<b>0.002</b>
BMI category (kg/m <sup>2</sup> )				
<25	25 (38)	19 (53)	6 (20)	<b>0.006</b>
≥25	41 (62)	17 (47)	24 (80)	
Smoking habit				
No	61 (94)	33 (92)	28 (97)	0.6
Yes	4 (6.2)	3 (8.3)	1 (3.4)	
Unknown	1	0	1	
Clinical staging (TNM)				
Stages 0 and I	18 (30)	11 (32)	7 (26)	0.6
Stages II and III	43 (70)	23 (68)	20 (74)	
NA	5	2	3	
Type of surgery				
Prophylactic	5 (7.6)	2 (5.6)	3 (10)	0.7
Therapeutic	61 (92)	34 (94)	27 (90)	
Laterality				
Right	31 (47)	17 (47)	14 (47)	>0.9
Left	35 (53)	19 (53)	16 (53)	
Type of incision				
Periareolar	14 (21)	3 (8.3)	11 (37)	<b>&lt;0.001</b>
Radial	6 (9.1)	0 (0)	6 (20)	
Inframammary fold	33 (50)	33 (92)	0 (0)	
Inverted T	13 (20)	0 (0)	13 (43)	
Histology				
Normal breast	5 (7.6)	2 (5.6)	3 (10)	0.8
Invasive carcinoma	53 (80)	29 (81)	24 (80)	
DCIS	8 (12)	5 (14)	3 (10)	
Histologic grade				
I	15 (25)	7 (21)	8 (30)	0.5
II	33 (54)	18 (53)	15 (56)	
III	13 (21)	9 (26)	4 (15)	
NA	5	2	3	
IHC				
HR(-)/HER2(3+)	10 (16)	4 (12)	6 (22)	0.2
HR(-)/HER2(neg)	5 (8.2)	4 (12)	1 (3.7)	
HR(+)/HER2(3+)	12 (20)	9 (26)	3 (11)	
HR(+)/HER2(neg)	34 (56)	17 (50)	17 (63)	
NA	5	2	3	

Continue...

**Table 1.** Continuation.

Variables	Total n=66* (%)	Prepectoral n=36* (%)	Subpectoral n=30* (%)	p-value†
<b>Focality</b>				
Multifocal	15 (25)	9 (26)	6 (22)	0.7
Unifocal	46 (75)	25 (74)	21 (78)	
NA	5	2	3	
<b>Margin assessment</b>				
Free	59 (97)	32 (94)	27 (100)	0.5
Involved (superficial)	2 (3.3)	2 (5.9)	0 (0)	
NA	5	2	3	
<b>Axillary surgery</b>				
Not performed	7 (11)	3 (8.3)	4 (13)	0.4
SLNB	47 (71)	28 (78)	19 (63)	
Lymph node excision	12 (18)	5 (14)	7 (23)	
<b>Number of dissected lymph nodes</b>				
≤4	47 (71)	27 (75)	20 (67)	0.5
>4	19 (29)	9 (25)	10 (33)	
<b>Number of involved lymph nodes</b>				
≤4	63 (95)	35 (97)	28 (93)	0.6
>4	3 (4.5)	1 (2.8)	2 (6.7)	
Prosthesis size (cc)	418 (360–475)	380 (339–429)	440 (414–508)	<b>&lt;0.001</b>
Breast weight (g)	352 (262–482)	276 (222–347)	499 (387–663)	<b>&lt;0.001</b>
Surgery time (minutes)	145 (116–199)	123 (110–153)	195 (145–253)	<b>&lt;0.001</b>
<b>Symmetrization</b>				
No	40 (61)	27 (75)	13 (43)	<b>0.009</b>
Yes	26 (39)	9 (25)	17 (57)	
<b>Adjuvant radiotherapy</b>				
No	40 (61)	22 (61)	18 (60)	>0.9
Yes	26 (39)	14 (39)	12 (40)	
<b>Neoadjuvant CT</b>				
No	35 (53)	18 (50)	17 (57)	0.6
Yes	31 (47)	18 (50)	13 (43)	
<b>Implant extrusion</b>				
Yes	8 (12)	6 (17)	2 (6.7)	0.3
No	58 (88)	30 (83)	28 (93)	
Time until extrusion (days)	146.8 (27–391)	180 (84–391)	48.5 (27–70)	<b>0.066</b>
<b>Staff</b>				
A	21 (32)	15 (42)	6 (20)	0.074
B	21 (32)	8 (22)	13 (43)	
C	9 (14)	7 (19)	2 (6.7)	
D	7 (11)	2 (5.6)	5 (17)	
E	8 (12)	4 (11)	4 (13)	

BMI: Body Mass Index; NA: Not applicable; DCIS: ductal carcinoma in situ; IHC: immunohistochemical profile; SLNB: sentinel lymph node biopsy; CT: chemotherapy. \*Absolute numbers: interquartile range and frequencies; †Student's t-test or Mann-Whitney test; Fisher's Exact Test or  $\chi^2$  of independent samples. Bold indicates statistically significant p-values.

**Table 2.** Characterization of variables according to the outcome of extrusion versus no implant extrusion.

Variables	Total n=66* (%)	With extrusion n=8* (%)	No extrusion n=58* (%)	p-value†
Age (years)	48 (41–53)	51 (43–54)	48 (41–53)	0.8
Age group				
≤45	28 (42)	3 (38)	25 (43)	>0.9
>45	38 (58)	5 (63)	33 (57)	
BMI (kg/m <sup>2</sup> )	25.8 (23.7–27.9)	26.1 (24.5–27.6)	25.8 (23.5–27.9)	0.8
BMI category				
<25	25 (38)	3 (38)	22 (38)	>0.9
≥25	41 (62)	5 (63)	36 (62)	
Smoking habit				
No	61 (94)	7 (88)	54 (95)	0.4
Yes	4 (6.2)	1 (13)	3 (5.3)	
Unknown	1	0	1	
Type of surgery				
Prophylactic	5 (7.6)	0 (0)	5 (8.6)	>0.9
Therapeutic	61 (92)	8 (100)	53 (91)	
Histology				
Normal breast	5 (7.6)	0 (0)	5 (8.6)	0.6
Invasive carcinoma	53 (80)	8 (100)	45 (78)	
DCIS	8 (12)	0 (0)	8 (14)	
Histologic grade				
I	15 (25)	1 (13)	14 (26)	0.6
II	33 (54)	6 (75)	27 (51)	
III	13 (21)	1 (13)	12 (23)	
NA	5	0	5	
IHC				
HR(-)/HER2(3+)	10 (16)	2 (25)	8 (15)	0.7
HR(-)/HER2(neg)	5 (8.2)	0 (0)	5 (9.4)	
HR(+)/HER2(3+)	12 (20)	2 (25)	10 (19)	
HR(+)/HER2(neg)	34 (56)	4 (50)	30 (57)	
NA	5	0	5	
Clinical staging (TNM)				
Stages 0 and I	18 (30)	1 (13)	17 (32)	0.4
Stages II and III	43 (70)	7 (88)	36 (68)	
NA	5	0	5	
Focality				
Multifocal	15 (25)	2 (25)	13 (25)	>0.9
Unifocal	46 (75)	6 (75)	40 (75)	
NA	5	0	5	
Laterality				
Right	31 (47)	2 (25)	29 (50)	0.3
Left	35 (53)	6 (75)	29 (50)	

Continue...

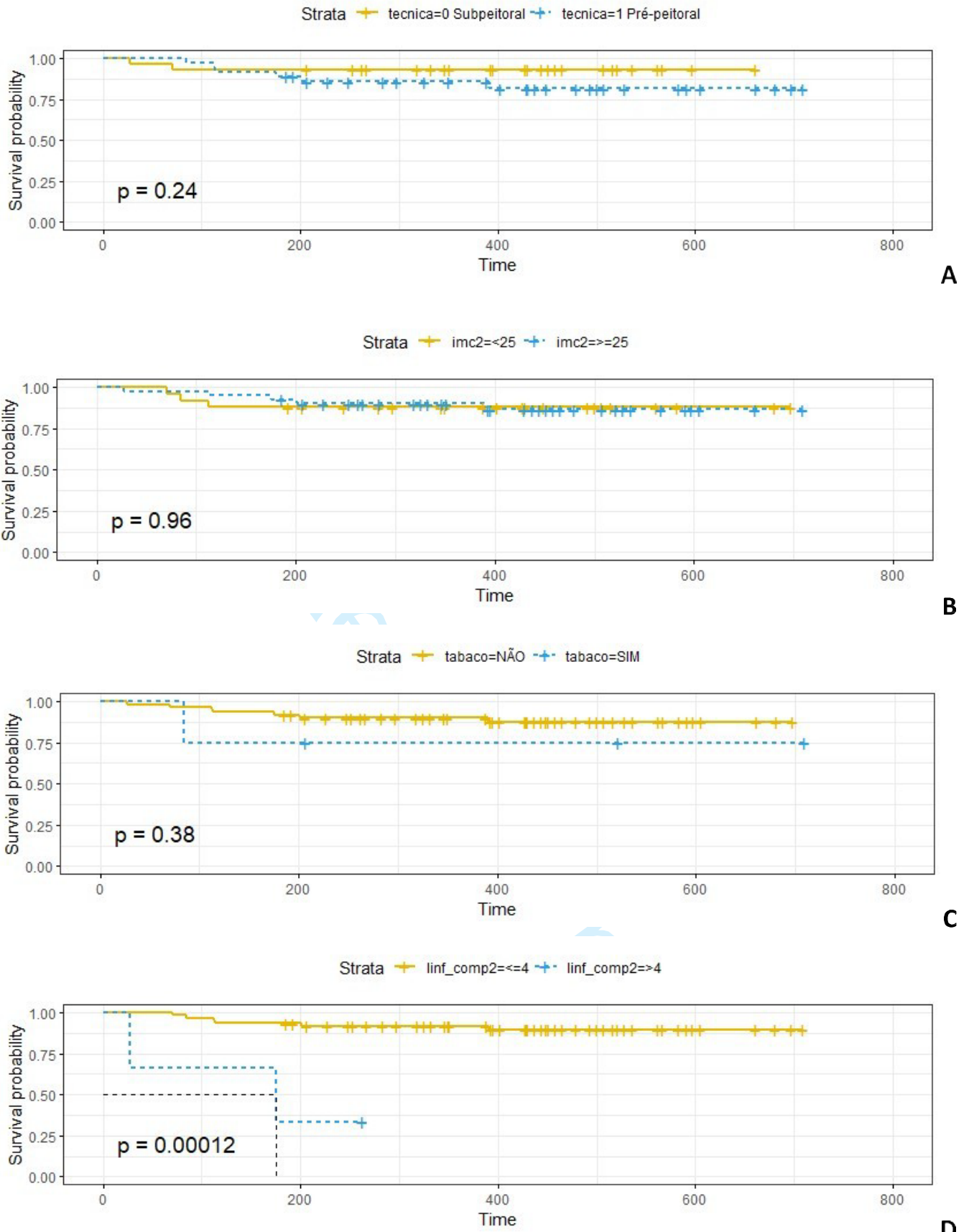
**Table 2.** Continuation.

Variables	Total n=66* (%)	With extrusion n=8* (%)	No extrusion n=58* (%)	p-value†
Type of incision				
Periareolar	11 (17)	1 (13)	10 (17)	0.8
Radial ULQ	6 (9.1)	0 (0)	6 (10)	
Inframammary fold	36 (55)	6 (75)	30 (52)	
Inverted T	13 (20)	1 (13)	12 (21)	
Margin				
Free	59 (97)	7 (88)	52 (98)	0.2
Involved (superficial)	2 (3.3)	1 (13)	1 (1.9)	
NA	5	0	5	
Axillary surgery				
Not performed	7 (11)	0 (0)	7 (12)	0.010
SLNB	47 (71)	3 (38)	44 (76)	
Lymph node excision	12 (18)	5 (63)	7 (12)	
Number of dissected lymph nodes				
≤4	47 (71)	5 (63)	44 (76)	<b>0.7</b>
>4	19 (29)	3 (38)	16 (28)	
Number of involved lymph nodes				
≤4	63 (95)	6 (75)	57 (98)	0.037
>4	3 (4.5)	2 (25)	1 (1.7)	
Prosthesis size (cc)	418 (360–475)	465 (370–506)	410 (360–469)	0.4
Breast weight (g)	352 (262–482)	407 (243–455)	349 (262–508)	>0.9
Breast weight				
<425	43 (65)	4 (50)	39 (67)	0.4
≥425	23 (35)	4 (50)	19 (33)	
Surgery time (minutes)	145 (116–199)	160 (119–209)	145 (116–195)	0.7
Symmetrization				
No	40 (61)	6 (75)	34 (59)	0.5
Yes	26 (39)	2 (25)	24 (41)	
Adjuvant radiotherapy				
No	40 (61)	4 (50)	36 (62)	0.7
Yes	26 (39)	4 (50)	22 (38)	
Neoadjuvant chemotherapy				
No	35 (53)	2 (25)	33 (57)	0.13
Yes	31 (47)	6 (75)	25 (43)	
Technique				
Subpectoral	30 (45)	2 (25)	28 (48)	0.3
Prepectoral	36 (55)	6 (75)	30 (52)	
Staff				
A	21 (32)	3 (38)	18 (31)	0.2
B	21 (32)	1 (13)	20 (34)	
C	9 (14)	3 (38)	6 (10)	
D	7 (11)	0 (0)	7 (12)	
E	8 (12)	1 (13)	7 (12)	

BMI: Body Mass Index; DCIS: ductal carcinoma in situ; NA: Not applicable; IHC: immunohistochemical profile; ULQ: upper lateral quadrant; SLNB: sentinel lymph node biopsy.

\*Median (interquartile range); †Wilcoxon test; Fisher's exact test. Bold indicates statistically significant p-values.





**Figure 1.** Implant loss-free survival. A: prepectoral technique vs. subpectoral technique; B: BMI 25; C: smoking habit yes vs. no; D: No. of involved lymph nodes  $\leq 4$  vs.  $>4$ .



**Table 3.** Cox survival model analysis relating time to outcome (implant extrusion) with independent variables.

Variables	No. of events	HR	95%CI	p-value	q-value*
Age group (years)	8			0.25	0.56
≤45		—	—		
>45		2.91	0.44–19.1		
BMI (kg/m <sup>2</sup> )	8			0.51	0.57
<25		—	—		
≥25		0.52	0.07–3.71		
Neoadjuvant CT	8			0.24	0.56
No		—	—		
Yes		3.60	0.38–34.0		
Adjuvant radiotherapy	8			0.40	0.57
No		—	—		
Yes		2.25	0.33–15.2		
Surgical technique	8			0.28	0.56
Subpectoral		—	—		
Prepectoral		5.19	0.20–135		
Surgery time (minutes)	8	1.00	0.99–1.02	0.48	0.57
Number of dissected lymph nodes	8			0.31	0.56
≤4		—	—		
>4		0.26	0.01–4.71		
Number of involved lymph nodes	8			<b>0.007</b>	<b>0.075</b>
≤4		—	—		
>4		76.6	2.29–2-558		
Clinical staging (TNM)	8			0.43	0.57
0-I		—	—		
II-III		2.61	0.21–32.1		
Smoking habit	8			0.090	0.49
No		—	—		
Yes		16.3	0.91–294		
Breast weight (g)	8	1.00	1.00–1.01	0.71	0.71

\*False discovery rate for multiple tests.

HR: hazard ratio; CI: confidence interval; BMI: Body Mass Index; CT: chemotherapy; Bold indicates statistically significant p-values.

Among the factors linked to the demographic profile that may be associated with an increased rate of complications are high BMI (over 30 kg/m<sup>2</sup>) and breast weight<sup>3,14,16</sup>. In the present analysis, the general profile of the sample was similar to that of other publications and there was no statistical relevance in the comparison of patients who had or did not have extrusion (p=0.51 for BMI and p>0.71 for breast weight), similar to the results demonstrated by Hassan et al., 2021 who, despite finding a higher occurrence of implant loss in the group with higher BMI, did not demonstrate statistical significance<sup>21</sup>.

In the comparative analysis of the subgroups, it was evident that patients who underwent subpectoral reconstruction had significantly higher BMI and breast weight, with p=0.002 and

0.001, respectively, as described by Sbitany et al.<sup>22</sup> The prosthesis size was also relevant in this comparison, with a larger prosthesis size in the subpectoral reconstruction group, with p<0.05. As this is a real-life, retrospective, cohort study, the selection of patients for each reconstruction technique was at the surgeon's discretion. Thus, there is selection bias between the groups, with a predominance of smaller breasts and implants in the prepectoral group. This fact was expected because this reconstruction technique is more commonly indicated for patients with smaller breasts and absent ptosis or ptosis up to grade 2<sup>9</sup>.

Based on morphological criteria, patients with larger breasts require larger volume prosthesis for reconstruction. This fact alone has a greater relationship with the risk of flap ischemia due

to compression of the subdermal vessels<sup>22</sup>. Greater volume and increased ptosis are other factors that lead to an increased risk of ischemia and necrosis of the skin and NAC, therefore requiring an additional layer for protection, suggesting the indication for submuscular reconstruction<sup>14</sup>.

The median age in the assessed population was 48 years and, in the subgroup analysis, there was no statistical difference in this regard ( $p=0.7$ ). The relationship between age above or below 45 years of women with or without extrusion was also not significant ( $p=0.8$ ). Advanced age is a recognized factor associated with a higher incidence of complications<sup>23</sup>. However, although this population demonstrated similarity with those of other studies, the relevance of this factor for extrusions was not demonstrated in these studies<sup>21-23</sup>. In the present research, advanced age did not represent a contraindication for reconstructions. The evaluation of indication depended on the surgeon's judgment regarding the performance status of each individual and the observation of other associated risk factors.

Smoking habit was reported by only 6.2% of patients, having low representation in this sample. The rates for this datum vary according to the time and location of the study<sup>24</sup>. In Brazil, the prevalence of smoking has decreased over the years<sup>25</sup>. Its greater association with the risk of ischemic complications and implant loss makes it a relative contraindication, which may also have impacted the decision regarding the indication for reconstruction in this population<sup>9,14,23,26</sup>.

Prepectoral reconstructions were associated with a lower rate of contralateral symmetrization when compared to subpectoral reconstructions (25% versus 57%,  $p=0.009$ ), in addition to shorter surgical time ( $p=0.001$ ), as shown by Franceschini et al.<sup>9</sup> The correlation of shorter time of the prepectoral technique can be justified by the lack of need for dissection of the submuscular space for insertion of the prosthesis and by the lower number of contralateral breast symmetrization. In this technique, the occupation of the gland's own anatomical space by the prosthesis provided a more natural aesthetic appearance, simulating contour and ptosis similar to its previous conformation<sup>14-16</sup>.

In subpectoral reconstructions, the least common incision was the radial one (9.1%), possibly due to its recurrent relationship with displacement of the NAC due to scar retraction that is apparent in the anterior view, leading to an unfavorable aesthetic result<sup>20,27,28</sup>. Periareolar incisions (37%), still highly recommended due to good access for mastectomy, axillary approach, and creation of the submuscular pocket, maintain the inconvenience of the scar in the anterior view and are losing preference<sup>29</sup>.

In the subpectoral reconstruction population, there was a greater number of women with large breasts and, consequently, higher levels of ptosis, as such factors are related to a greater risk of complications in prepectoral reconstruction<sup>9,14,22</sup>. These characteristics indicate a greater possibility of the need for resection

of excess skin, justifying a high rate of reduction mammoplasty-type incisions (43%) for a better aesthetic result<sup>20,30</sup>.

Incisions through the inframammary fold were sometimes associated with greater risks due to the supposed greater tension in the suture line, as well as the possibility of venous congestion and circulatory deficit in the lower area of the flap, but in this population this datum was not relevant regarding the risk of extrusion ( $p=0.46$ )<sup>31</sup>. This incision was the most commonly chosen, applied in all prepectoral reconstructions, and it was not significant regarding the association with risk of extrusion (OR 2.00; 95%CI 0.29–40.2 and  $p=0.46$ ), as shown in other publications<sup>10,32</sup>. This preference is justified by providing good access for performing the procedure, a scar in a barely visible location, and preservation of the positioning of the NAC<sup>20,27,28</sup>.

Variables linked to complementary treatment, such as exposure to radiotherapy and chemotherapy, are known risk factors for prosthesis extrusion<sup>3,8,21</sup>. In this research, neither of these two factors had statistical relevance regarding extrusion, either through univariate analysis or the Cox model, results similar to recent publications<sup>9,31,33</sup>. The decrease in the effects of complementary therapies on implant loss rates may be related to the evolution of surgical techniques used, as well as the consolidation of knowledge of oncological safety in conservative mastectomies<sup>5,22</sup>.

Researchers of most publications demonstrate correlations of factors linked to the individual or the treatment regarding their influence on complications or describe complication rates in a population undergoing one of the reconstruction techniques<sup>3,34,35</sup>. As for tumor characteristics, there are few studies discussing their relevance regarding the influence on complication rates. In this context, characteristics — such as tumor type, histologic grade, immunohistochemical expression, and focality — were detailed in the present study. Invasive ductal carcinoma of no special type (IDC) was the most frequent type (61%), as described in other populations<sup>3,31,35</sup>. In the univariate analysis, this aspect was not statistically significant ( $p=0.2$ ), corroborating Blok et al.<sup>35</sup>. Histologic grade, immunohistochemical expression, and focality were also irrelevant for the analyzed outcome. These results allow us to assume that tumor characteristics are in the background regarding the influence on the risk of extrusion.

Among other aspects evaluated in this analysis, the type of axillary approach has statistical relevance according to the univariate analysis, as 63% of prosthesis losses occurred in patients who underwent axillary lymph node excision ( $p=0.01$ ) and in those who presented a greater number of involved lymph nodes ( $p=0.037$ ). Jafferbhoy et al., demonstrated similar data, however, they did not analyze characteristics such as staging or volume of tumor involvement, variables directly linked to the indication of this type of axillary approach<sup>6</sup>. Within this context, women who had only neoplasia *in situ* (12%) did not have extrusion, and among those clinically staged at 0 and I, only one evolved with implant loss. Thus, when the clinical stage was related to

the outcome, more than half of the events occurred in patients classified as stage II and III. Elswick et al., reached conflicting results regarding complication rates, such as higher necrosis and dehiscence rates in the group of patients undergoing adjuvant radiotherapy, in a population in which 50% of patients were classified as stage III<sup>34</sup>.

Another relevant aspect was the degree of axillary involvement in the histopathological analysis. In this case, there was a significance with a predominance in those who had a smaller volume of axillary disease, that is, up to four involved lymph nodes ( $p=0.037$ ). However, only three women had high lymph node involvement. Therefore, these factors were included in the multivariate analysis in order to clarify discordant results.

Based on preestablished clinical criteria, variables related to a higher risk of postoperative breast complications were included in a multivariate analysis using the Cox survival model, in which a statistical correlation was observed with the degree of axillary involvement, reinforcing the assumption linked to the clinical stage. The group with greater axillary involvement (>4 lymph nodes) presented a higher risk ratio (HR 2.29; 95%CI 2.5–58). This datum indicates that axillary tumor volume may represent a risk factor for implant loss in single-stage immediate breast reconstructions. Nonetheless, individuals with this involvement profile are also included in the list of indications for chemotherapy and radiotherapy, possible confounding factors<sup>36,37</sup>.

These aspects, despite not having demonstrated significance in this analysis, are widely correlated with the outcome according to previous analyses<sup>31,38</sup>. Therefore, it is necessary to include variables linked to the clinical stage and tumor volume in the final histopathological analysis, in studies with a larger population and more extrusion events.

## CONCLUSIONS

Immediate reconstruction after skin- and nipple-sparing mastectomy with prepectoral implant placement without the use of cell dermal matrix was not associated with a higher risk of extrusion when compared with the submuscular technique. Large axillary involvement was the only factor associated with implant loss in this population. The study results may be limited by sample selection bias.

## AUTHORS' CONTRIBUTION

PLC: Data curation, Formal analysis, Writing – original draft. YCMSR: Supervision, Validation. GMC: Supervision, Validation, Writing – review & editing. AGCO: Supervision, Validation, Writing – review & editing. RAV: Supervision, Validation. JPG: Conceptualization, Methodology, Project administration, Supervision, Writing – review & editing.

## REFERENCES

- Sung H, Ferlay J, Siegel RL, Laversanne M, Soerjomataram I, Jemal A, et al. Global Cancer Statistics 2020: GLOBOCAN estimates of incidence and mortality worldwide for 36 cancers in 185 countries. *CA Cancer J Clin.* 2021;71(3):209-49. <https://doi.org/10.3322/caac.21660>
- Brasil. Ministério da Saúde. Instituto Nacional de Câncer. Outubro rosa 2022 [cited on 2023 Mar. 29]. Available from: <https://www.gov.br/inca/pt-br/assuntos/campanhas/2022/outubro-rosa#:~:text=Com%20o%20tema%20%22Eu%20cuido,precoce%20e%20rastreamento%20da%20doen%C3%A7a>
- McDonald E, Clark AS, Tchou J, Zhang P, Freedman GM. Clinical diagnosis and management of breast cancer. *J Nucl Med.* 2016;57 Suppl 1:9S-16S. <https://doi.org/10.2967/jnumed.115.157834>
- Frasson A, Novita G, Millen E, Felipe Z, Pimentel F, Brenelli F, et al. Doenças da mama: guia baseado em evidências. 2ª ed. Rio de Janeiro: Atheneu; 2018.
- Chopra S, Al-Ishaq Z, Vidya R. The journey of prepectoral breast reconstruction through time. *World J Plast Surg.* 2021;10(2):3-13. <https://doi.org/10.29252/wjps.10.2.3>
- Jafferbhoy S, Chandarana M, Houlihan M, Parmeshwar R, Narayanan S, Soumian S, et al. Early multicenter experience of pre-pectoral implant based immediate breast reconstruction using Braxon®. *Gland Surg.* 2017;6(6):682-8. <https://doi.org/10.21037/gs.2017.07.07>
- Ribuffo D, Berna G, Vita R, Di Benedetto G, Cigna E, Greco M, et al. Dual-plane retro-pectoral versus pre-pectoral dti breast reconstruction: an Italian multicenter experience. *Aesthetic Plast Surg.* 2021;45(1):51-60. <https://doi.org/10.1007/s00266-020-01892-y>
- Manrique OJ, Huang TC, Martinez-Jorge J, Ciudad P, Forte AJ, Bustos SS, et al. Prepectoral two-stage implant-based breast reconstruction with and without acellular dermal matrix: do we see a difference? *Plast Reconstr Surg.* 2020;145(2):263e-272e. <https://doi.org/10.1097/PRS.00000000000006442>
- Franceschini G, Scardina L, Di Leone A, Terribile DA, Sanchez AM, Magno S, et al. Immediate prosthetic breast reconstruction after nipple-sparing mastectomy: traditional subpectoral technique versus direct-to-implant prepectoral reconstruction without acellular dermal matrix. *J Pers Med.* 2021;11(2):153. <https://doi.org/10.3390/jpm11020153>
- Urban C, González E, Fornazari A, Berman G, Spautz C, Kuroda F, et al. Prepectoral direct-to-implant breast reconstruction without placement of acellular dermal matrix or mesh after nipple-sparing mastectomy. *Plast Reconstr Surg.* 2022;150(5):973-83. <https://doi.org/10.1097/PRS.00000000000009618>

11. Jones G, Antony AK. Single stage, direct to implant prepectoral breast reconstruction. *Gland Surg.* 2019;8(1):53-60. <https://doi.org/10.21037/ggs.2018.10.08>
12. Snyderman RK, Guthrie RH. Reconstruction of the female breast following radical mastectomy. *Plast Reconstr Surg.* 1971;47(6):565-7. <https://doi.org/10.1097/00006534-197106000-00008>
13. Schlenker JD, Bueno RA, Ricketson G, Lynch JB. Loss of silicone implants after subcutaneous mastectomy and reconstruction. *Plast Reconstr Surg.* 1978;62(6):853-61. <https://doi.org/10.1097/00006534-197812000-00004>
14. Franceschini G, Masetti R. Immediate implant-based breast reconstruction with acellular dermal matrix after conservative mastectomy: can a more effective alternative be used in the near future? *Eur J Surg Oncol.* 2021;47(5):1225-6. <https://doi.org/10.1016/j.ejso.2020.09.037>
15. Cuomo R. Submuscular and pre-pectoral ADM assisted immediate breast reconstruction: a literature review. *Medicina (Kaunas).* 2020;56(6):256. <https://doi.org/10.3390/medicina56060256>
16. Vita R, Buccheri EM, Villanucci A, Pozzi M. Breast reconstruction actualized in nipple-sparing mastectomy and direct-to-implant, prepectoral polyurethane positioning: early experience and preliminary results. *Clin Breast Cancer.* 2019;19(2):e358-e363. <https://doi.org/10.1016/j.clbc.2018.12.015>
17. Salibian AH, Harness JK, Mowlds DS. Staged suprapectoral expander/implant reconstruction without acellular dermal matrix following nipple-sparing mastectomy. *Plast Reconstr Surg.* 2017;139(1):30-9. <https://doi.org/10.1097/PRS.0000000000002845>
18. Adam H, Bygdeson M, de Boniface J. The oncological safety of nipple-sparing mastectomy: a Swedish matched cohort study. *Eur J Surg Oncol.* 2014;40(10):1209-15. <https://doi.org/10.1016/j.ejso.2014.07.037>
19. Franceschini G, Masetti R. Evidence-based nipple-sparing mastectomy in patients with higher body mass index: recommendations for a successful standardized surgery. *Am J Surg.* 2020;220(2):393-4. <https://doi.org/10.1016/j.amjsurg.2020.01.002>
20. Daar DA, Abdou SA, Rosario L, Rifkin WJ, Santos PJ, Wirth GA, et al. Is there a preferred incision location for nipple-sparing mastectomy? A systematic review and meta-analysis. *Plast Reconstr Surg.* 2019;143(5):906e-919e. <https://doi.org/10.1097/PRS.0000000000005502>
21. Hassan R, Urban CA, Doria MT, Spautz CC, Rabinovich I, Anselmi KF, et al. Exposed implant after immediate breast reconstruction – presentation and analysis of a clinical management protocol. *Rev Bras Ginecol Obstet.* 2021;43(9):690-8. <https://doi.org/10.1055/s-0041-1735939>
22. Sbitany H, Gomez-Sanchez C, Piper M, Lentz R. Prepectoral breast reconstruction in the setting of postmastectomy radiation therapy: an assessment of clinical outcomes and benefits. *Plast Reconstr Surg.* 2019;143(1):10-20. <https://doi.org/10.1097/PRS.0000000000005140>
23. Downs RK, Hedges K. An alternative technique for immediate direct-to-implant breast reconstruction – a case series. *Plast Reconstr Surg Glob Open.* 2016;4(7):e821. <https://doi.org/10.1097/GOX.0000000000000839>
24. World Health Organization. WHO report on the global tobacco epidemic 2019: offer help to quit tobacco use. Geneva: World Health Organization; 2019.
25. Brasil. Ministrio da Sade. Instituto Nacional de Cncer. Data and smoking numbers. Data about prevalence, diseases, mortality, costs, tobacco production and exportation and per capita consumption. Ministrio da Sade; 2022 [cited on 2024 Sept. 4]. Available from: <https://www.gov.br/inca/en/topics/health-professional/observatory-of-the-national-policy-on-tobacco-control/data-and-smoking-numbers>
26. Mirhaidari SJ, Azouz V, Wagner DS. Prepectoral versus subpectoral direct to implant immediate breast reconstruction. *Ann Plast Surg.* 2020;84(3):263-70. <https://doi.org/10.1097/SAP.0000000000002059>
27. Colwell AS, Gadd M, Smith BL, Austen Jr WG. An inferolateral approach to nipple-sparing mastectomy: optimizing mastectomy and reconstruction. *Ann Plast Surg.* 2010;65(2):140-3. <https://doi.org/10.1097/SAP.0b013e3181c1fe77>
28. Endara M, Chen D, Verma K, Nahabedian MY, Spear SL. Breast reconstruction following nipple-sparing mastectomy: a systematic review of the literature with pooled analysis. *Plast Reconstr Surg.* 2013;132(5):1043-54. <https://doi.org/10.1097/PRS.0b013e3182a48b8a>
29. Salibian AH, Harness JK, Mowlds DS. Inframammary approach to nipple-areola-sparing mastectomy. *Plast Reconstr Surg.* 2013;132(5):700e-708e. <https://doi.org/10.1097/PRS.0b013e3182a4d64f>
30. Irwin GW, Black A, Refsum SE, McIntosh SA. Skin-reducing mastectomy and one-stage implant reconstruction with a myodermal flap: a safe and effective technique in risk-reducing and therapeutic mastectomy. *J Plast Reconstr Aesthet Surg.* 2013;66(9):1188-94. <https://doi.org/10.1016/j.bjps.2013.04.048>
31. Apte A, Walsh M, Balaji P, Khor B, Chandrasekharan S, Chakravorty A. Single stage immediate breast reconstruction with acellular dermal matrix and implant: defining the risks and outcomes of post-mastectomy radiotherapy. *Surgeon.* 2020;18(4):202-7. <https://doi.org/10.1016/j.surge.2019.09.007>
32. Khan A, Tasoulis MK, Teoh V, Tanska A, Edmonds R, Gui G. Pre-pectoral one-stage breast reconstruction with anterior biological acellular dermal matrix coverage. *Gland Surg.* 2021;10(3):1002-9. <https://doi.org/10.21037/gs-20-652>
33. Safran T, Al-Halabi B, Viesel-Mathieu A, Boileau JF, Dionisopoulos T. Direct-to-implant, prepectoral breast reconstruction: a single-surgeon experience with 201 consecutive patients. *Plast Reconstr Surg.* 2020;145(4):686e-696e. <https://doi.org/10.1097/PRS.0000000000006654>
34. Elswick SM, Harless CA, Bishop SN, Schleck CD, Mandrekar J, Reusche RD, et al. Prepectoral implant-based breast reconstruction with postmastectomy radiation therapy. *Plast Reconstr Surg.* 2018;142(1):1-12. <https://doi.org/10.1097/PRS.0000000000004453>

35. Blok Y, van Lierop E, Plat VD, Corion LUM, Verduijn PS, Krekel NMA. Implant loss and associated risk factors following implant-based breast reconstructions. *Plast Reconstr Surg Glob Open*. 2021;9(7):e3708. <https://doi.org/10.1097/GOX.0000000000003708>
36. Jang JK, Sverdluk ER, Schechter NR. A radiation oncologist's guide to axillary management in breast cancer: a walk through the trials. *Curr Breast Cancer Rep*. 2019;11(4):293-302. <https://doi.org/10.1007/s12609-019-00330-6>
37. Montagna G, Mamtani A, Knezevic A, Brogi E, Barrio AV, Morrow M. Selecting node-positive patients for axillary downstaging with neoadjuvant chemotherapy. *Ann Surg Oncol*. 2020;27(11):4515-22. <https://doi.org/10.1245/s10434-020-08650-z>
38. Chatterjee A, Nahabedian MY, Allen G, Sporck M, Parekh M, Macarios D, et al. Assessing postsurgical outcomes with prepectoral breast reconstruction: a literature review and meta-analysis update. 2021;9(10):e3828. <https://doi.org/10.1097/GOX.0000000000003825>

